

### Coexistence of Cushing Syndrome From Functional Adrenal Adenoma and Addison Disease From Immune-Mediated Adrenalitis

Randall Colucci, DO; Rafael E. Jimenez, MD; William Farrar, MD; Ramiro Malgor, MD; Leonard Kohn, MD; and Frank L. Schwartz, MD

A 56-year-old woman presented with an incidental adrenal adenoma and physical examination findings that included moderate obesity, a slight cervicothoracic fat pad (“buffalo hump”), increased supraclavicular fat pads, and white abdominal striae. Biochemical workup revealed elevated levels of 24-hour urinary free cortisol but normal serum morning cortisol and suppressed levels of corticotropin, suggestive of adrenal-dependent Cushing syndrome. The resected adrenal gland revealed macronodular cortical hyperplasia with a dominant nodule. Other findings included an absent cortisol response to corticotropin stimulation, presence of serum anti-21-hydroxylase antibodies, and mononuclear cell infiltration—consistent with adrenalitis. The findings represent, to the authors’ knowledge, the first known case of a patient with coexistent functional cortisol-secreting macronodular adrenal tumor resulting in Cushing syndrome and immune-mediated adrenalitis resulting in Addison disease.

*J Am Osteopath Assoc.* 2012;112(6):374-379

Adrenal-dependent Cushing syndrome is a rare form of Cushing syndrome caused primarily by benign (90% of cases) or malignant (8% of cases) adrenal tumors or—more rarely—by bilateral micronodular (1% of cases) or macronodular (<1% of cases) adrenal hyperplasia.<sup>1</sup> Addison disease is the most common form of adrenal insufficiency, caused by the autoimmune destruction of the adrenal cortex. Although antibodies directed against the 21-hydroxylase enzyme are a common finding in patients with Addison disease, most investigators believe that this disease process is mediated by T cells.<sup>2,3</sup> Some cases of Addison disease are isolated, and other cases exist in association with autoimmune polyendocrine syndromes.<sup>3</sup>

We report the case of a patient presenting with adrenal-dependent Cushing syndrome, resulting from macronodular cortical hyperplasia with a dominant nodule, who simultaneously had an infiltrating autoimmune destructive process of the adrenal gland, which resulted in permanent adrenal insufficiency. Immunostaining of the resected adrenal tissue revealed the presence of Toll-like receptor 4 (TLR4) in the tumor, as well as TLR4 and TLR3 in the adrenal epithelial cells being destroyed by the mononuclear infiltrates.

#### Report of Case

In October 2006, a 56-year-old woman was referred to the Diabetes/Endocrine Center at Ohio University Heritage College of Osteopathic Medicine in Athens for evaluation of an incidental 2.7-cm left adrenal adenoma. A few weeks before this visit, the adenoma had been found incidentally by her primary care physician on magnetic resonance images when the patient was being evaluated for abdominal pain.

Her medical history included the following: hypertension, hypothyroidism caused by Hashimoto thyroiditis, macular degeneration, osteopenia, otosclerosis, vitiligo, and several posttraumatic fractures. Her past surgeries included tonsillectomy and adenoidectomy, lumbar disk surgery, bilateral patellar tendon releases, total right knee replacement, and right wrist surgery with metal plate placement. Her current medications were as follows: levothyroxine sodium, 50 µg daily; meloxicam, 7.5 mg twice daily; valsartan/hydrochlorothiazide, 160 mg/12.5 mg daily; and a daily over-the-counter vitamin supplement.

From the Appalachian Rural Health Institute Diabetes/Endocrine Center (Drs Colucci, Kohn, and Schwartz), Department of Family Medicine (Dr Colucci), Department of Biomedical Sciences (Drs Malgor and Kohn), and Department of Specialty Medicine (Dr Schwartz) at the Ohio University Heritage College of Osteopathic Medicine in Athens; the Department of Pathology (Dr Jimenez) and Department of Surgery (Dr Farrar) at The Ohio State University College of Medicine in Columbus; and Edison Biotechnology Institute at Ohio University in Athens and Interthyr Corporation in Marietta, Ohio (Dr Kohn).

**Financial Disclosures:** None reported.

Address correspondence to Randall Colucci, DO, Appalachian Rural Health Institute Diabetes/Endocrine Center, Ohio University Heritage College of Osteopathic Medicine, Castrop Center, Suite 200, Athens, OH 45701-2859.

E-mail: rcolucci@insight.rr.com

Submitted January 30, 2011; revision received August 11, 2011; accepted August 29, 2011.

The patient's social history indicated that she was married, had 1 adult child, and worked as a switchboard operator at a local hospital. She had never smoked, she consumed alcohol rarely, and she drank 2 cups of coffee per day. She walked occasionally for exercise. Her family history was significant for type 2 diabetes mellitus, hypertension, hyperlipidemia, and an adrenal cyst.

Review of the patient's systems revealed intermittent, episodic hypertension, headaches, dizziness, and 1 episode of near syncope. She also complained of hot flashes, some flushing, and rapid pulse. Physical examination revealed moderate obesity and a mild Cushingoid appearance, including a slight fat pad seen posteriorly at the cervicothoracic junction, increased supraclavicular fat pads, and white abdominal striae. She also had vitiligo on the extensor surfaces of her hands and elbows, as well as mild ecchymosis of the upper extremities.

Laboratory evaluation (Table) revealed elevated levels of 24-hour urinary free cortisol on 2 separate occasions, in March 2006 (159 µg/24 h) and November 2006 (158 µg/24 h). Separate tests for fractionated plasma catecholamines revealed slightly elevated levels of vanillylmandelic acid, at 7.8 mg/24 h (in November 2006), and

norepinephrine, at 524 pg/mL (in January 2006). Morning serum cortisol levels were found to be in the high range of normal on 2 occasions, in January 2006 (18.9 µg/dL) and November 2006 (20.7 µg/dL), and the morning level of serum corticotropin was suppressed (<5 pg/dL in November 2006). Levels of serum and 24-hour urine aldosterone were normal (2.1 ng/dL in January 2006 and 5 µg/24 h in November 2006, respectively).

Because of the patient's mild adrenergic symptoms and elevated urine catecholamine levels, a meta-iodobenzylguanidine scan was ordered as a precaution before surgery. The scan result was negative for pheochromocytoma. With the presumptive diagnosis of an adrenal-dependent cortisol-secreting adrenal adenoma, the patient was referred for surgery. A left laparoscopic adrenalectomy was performed without complication at The Ohio State University Medical Center in early March 2007. Approximately 2 months after the procedure, the patient's morning serum cortisol level was 0.2 µg/dL. The pathology report for the adrenal tissue revealed macronodular cortical hyperplasia with a dominant hyperplastic nodule and no evidence of malignancy (Figure 1).

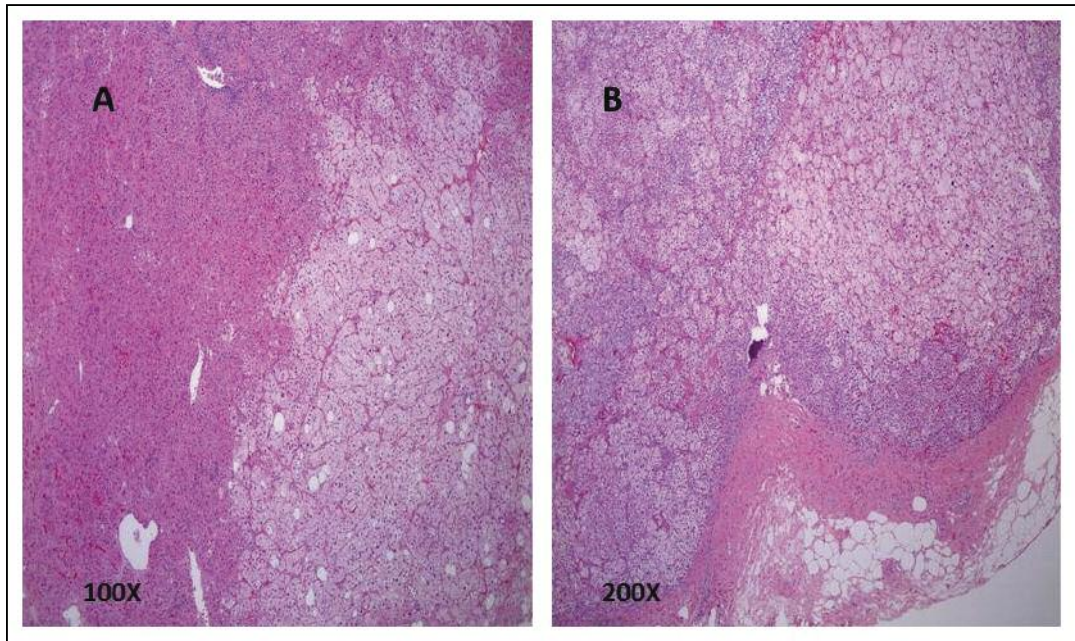
At discharge from the medical center in March 2007,

**Table.**  
**Endocrine and Laboratory Test Results for a 56-Year-Old Woman**

Assay/Test	Normal Values	Patient Values, by Date								
		1/13/06 <sup>a</sup>	3/4/06 <sup>a</sup>	11/4/06 <sup>b</sup>	2/15/07 <sup>c</sup>	5/24/07	7/17/07	8/29/07	12/9/07	1/11/08
<b>Aldosterone</b>										
Serum, ng/dL	≤31	2.1	...	...	...	...	...	...	...	...
Urine, µg/24 h	2-21	...	...	5	...	...	...	...	...	...
<b>Catecholamines, Fractionated, Plasma, pg/mL</b>										
Dopamine	0-20	20	...	...	...	...	...	...	...	...
Epinephrine	<10	<10	...	...	...	...	...	...	...	...
Norepinephrine	80-520	524	...	...	...	...	...	...	...	...
<b>Vanillylmandelic Acid, Urine, mg/24 h</b>	<b>1.8-6.7</b>	...	...	<b>7.8</b>	...	...	...	...	...	...
<b>Cortisol</b>										
Serum, morning, µg/dL	4.3-22.4	18.9	...	20.7	...	0.2	0.3	0.5	1.1	...
Urinary free, µg/24 h	<105	...	159	158	...	...	...	...	...	...
<b>Corticotropin, Serum, Morning, pg/mL</b>	<b>6-48</b>	...	...	<5	...	...	...	...	76	...
<b>Anti-21-hydroxylase Antibodies, U/mL</b>	<b>&lt;1.0</b>	...	...	...	...	...	...	...	...	131

<sup>a</sup> Laboratory tests ordered by primary care physician.  
<sup>b</sup> Laboratory tests ordered by endocrinologist upon initial consultation on October 31, 2006.  
<sup>c</sup> Patient's adrenalectomy performed in early March 2007.

## CASE REPORT



**Figure 1.** Hematoxylin and eosin–stained resected adrenal tissue of the patient at low magnification (A,  $\times 100$ ) and high magnification (B,  $\times 200$ ), revealing macronodular cortical hyperplasia with a dominant hyperplastic nodule and no evidence of malignancy.

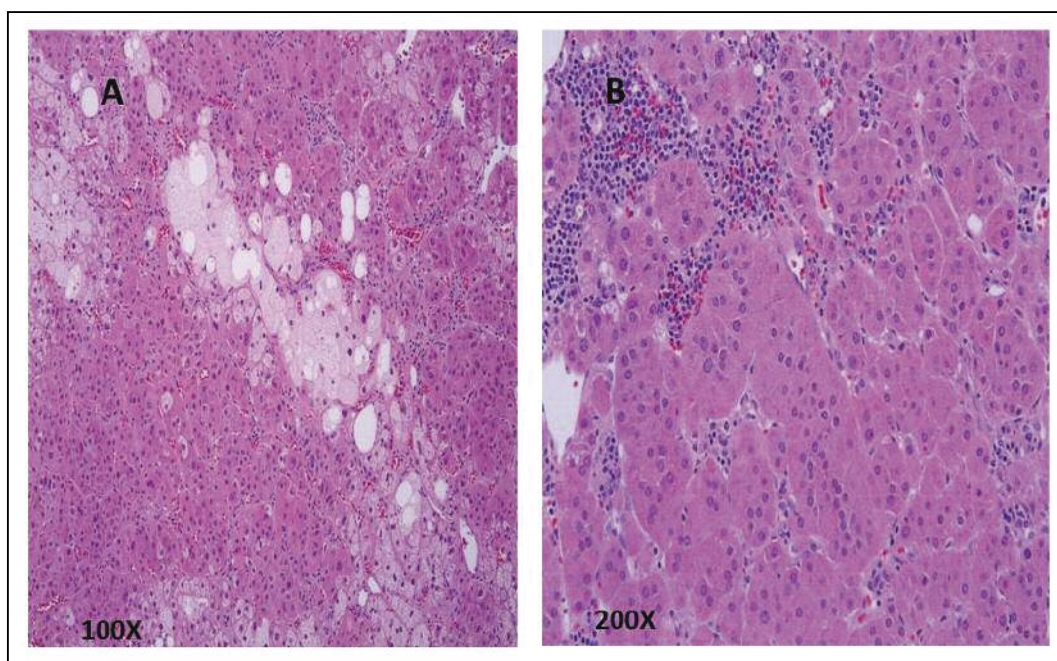
the patient was given hydrocortisone glucocorticoid, 25 mg twice daily, for several weeks, with the dose tapered to 10 mg twice daily over the next 6 weeks. The patient tolerated this medication and dose without apparent difficulty. During the first several months after surgery, the patient reported feeling much better, she regained muscle strength, and she lost about 22 pounds. Between May and November 2007, a complete weaning from oral steroids was attempted several times without success, and periodic morning serum cortisol levels were checked (*Table*). The patient continued to have low morning serum cortisol levels—presumably from either overreplacement with oral steroids or autoimmune destruction of her adrenal glands, causing less production of endogenous hormone. An alternate-day steroid taper was attempted in early December 2007 with hydrocortisone.

During the period from June to November 2007—when attempts to wean the patient from the steroid were attempted—the patient again reported feeling unwell, experiencing generalized myalgia, joint pain, and salt cravings. These symptoms were especially bad on the alternate days when she took the lower hydrocortisone doses or no hydrocortisone at all. Because the patient was still symptomatic despite about 6 months since her adrenalectomy and several trials of steroid weaning—and considering her known history of Hashimoto thyroiditis and

vitiligo—the possibility of permanent adrenal insufficiency from coexistent autoimmune destruction of the adrenal gland was seriously contemplated. Consequently, a test for serum anti-21-hydroxylase antibodies was performed in January 2008, yielding positive results for these antibodies. The patient was subsequently switched from alternate-day low-dose hydrocortisone to daily low-dose dexamethasone for slightly less than 1 week.

In December 2007, on a morning in which she had received no dexamethasone for 48 hours, her morning cortisol level was found to be low (1.1  $\mu\text{g}/\text{dL}$ ), and her morning corticotropin level was found to be high (76  $\text{pg}/\text{dL}$ ) (*Table*). The patient showed no response to the Cortrosyn stimulation test, which measures how well the adrenal glands respond to corticotropin. This result was highly suggestive of Addison disease, though it could also be the result of using high-dose oral replacement steroid.

The presence of anti-21-hydroxylase antibodies was suggestive of an autoimmune destructive process of the adrenal gland, rather than chronic hypothalamic-pituitary-adrenal suppression from the previous cortisol-secreting adrenal tumor or recent exogenous glucocorticoid replacement. To determine if an autoimmune inflammatory process was destroying adrenal tissue unaffected by the macronodular hyperplasia, thereby causing permanent adrenal insufficiency, paraffin sections from the patient's



**Figure 2.** Hematoxylin and eosin–stained adrenal tissue adjacent to the tumor at low magnification (A,  $\times 100$ ) and high magnification (B,  $\times 200$ ), revealing infiltration of the parenchyma by mononuclear inflammatory cells. The inflammatory cells predominated in association with capillaries within the connective tissue tracts in the gland.

previously resected adrenal tissue were reanalyzed. Hematoxylin and eosin staining of the adrenal tissue adjacent to the tumor revealed pathologically significant infiltration of the parenchyma by mononuclear inflammatory cells (Figure 2). The inflammatory cells predominated in association with capillaries within the connective tissue tracts in the gland.

Immunostaining revealed high levels of TLR4 in the dominant nodule (Figure 3A) and in the cytoplasm of adrenal epithelial cells that were being infiltrated by the inflammatory cells (ie, the sites of active adrenalitis) (Figure 3B). Test results for TLR4 were slightly positive in the inflammatory cells and endothelial cells of the capillaries and in the larger vessels within the adrenal gland. There was some positive TLR3 immunoreactivity in the adrenal epithelial cells, but there was no such immunoreactivity in the endothelial cells or inflammatory cells infiltrating the adrenal gland (Figure 3C). Immunostaining for Wnt5a (wingless-type MMTV integration site family, member 5A) showed negative results in the tumor tissue and adrenal epithelial cells (Figure 3D).

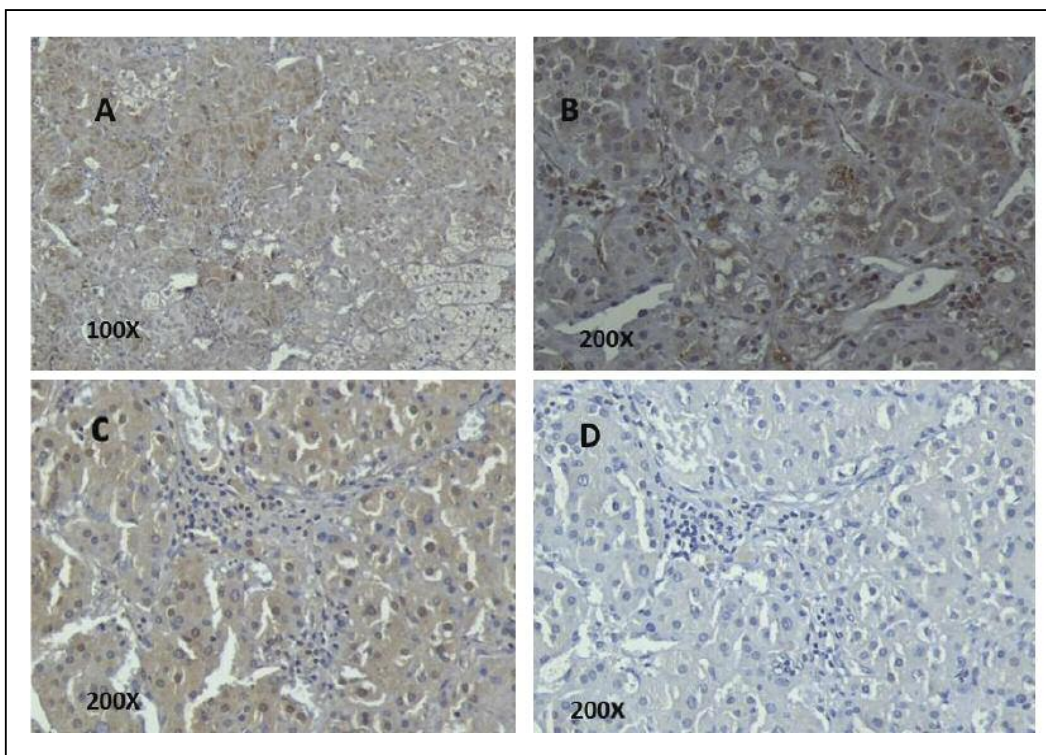
At her last follow-up appointment, in mid-2008, the patient was doing well. She remained asymptomatic about 1 month later, in July 2008. The patient, unfortunately, did not keep her subsequent follow-up appointments or complete ordered laboratory work.

### Comment

To our knowledge, the present case report is the first description of a patient with coexistent adrenal-dependent Cushing syndrome from macronodular hyperplasia and autoimmune-mediated Addison disease, which was masked by the functional tumor. The patient presented with a 2.7-cm adrenal adenoma, causing the macronodular adrenal hyperplasia to not be appreciated until pathologic evaluation of the resected adrenal gland.

A previous National Institutes of Health review of patients with macronodular adrenal hyperplasia revealed that 7 of 9 patients with hyperplastic adrenal glands also had bilateral single or multiple focal adrenal nodules.<sup>4</sup> The finding of macronodular adrenal hyperplasia in our patient suggests possible bilateral adrenal involvement. She exhibited permanent adrenal insufficiency as a result of autoimmune destruction of the cortisol-secreting cells, presumably involving both adrenals. She would have been monitored periodically with magnetic resonance imaging of her right adrenal gland if she had attended her follow-up appointments.

We present evidence that the patient's adrenal insufficiency was immune mediated, with the presence of serum anti-21-hydroxylase antibodies, lymphocytic infiltration of the adrenal epithelial cells adjacent to the tumor, and positive immunostaining results for TLR4 and TLR3. Detection



**Figure 3.** Immunostaining of the patient's adrenal tissue reveals high levels of Toll-like receptor 4 (TLR4) in the dominant nodule (A), as well as in the cytoplasm of adrenal epithelial cells that were being infiltrated by the inflammatory cells (B). Staining also showed TLR4 in some of the inflammatory cells and in endothelial cells of the capillaries and larger vessels within the adrenal gland (B). Positive TLR3 immunoreactivity results were seen in the adrenal epithelial cells but not in endothelial cells or inflammatory cells infiltrating the adrenal gland (C). Immunostaining for Wnt-5a (wingless-type MMTV integration site family, member 5A) showed negative results in the tumor tissue and adrenal epithelial cells (D).

of adrenalitis-associated antibodies to 21-hydroxylase, 17-hydroxylase, and the cytochrome P450 side-chain cleavage enzyme has been used clinically to predict risk for, as well as to classify the cause of, adrenal insufficiency.<sup>5,6</sup> The patient also had evidence of other autoimmune conditions, including hypothyroidism secondary to Hashimoto thyroiditis and vitiligo.

Toll-like receptors are a family of cell-surface or endosomal receptors (originally observed on immune cells) that initiate proinflammatory signaling pathways in response to pathogen-associated molecular patterns.<sup>7</sup> Overexpression of TLRs and TLR signaling on nonimmune cells, particularly involving TLR3, TLR4, and TLR9, are now accepted as the basis for the induction of autoimmune/inflammatory diseases (eg, autoimmune thyroiditis, colitis, systemic lupus erythematosus, type 1 diabetes mellitus), as well as for the growth and spread of certain malignancies (eg, malignant melanoma and cancers of the breast, colon, pancreas, papillary thyroid, and prostate).<sup>8-11</sup> Toll-

like receptor 9 has previously been described in human adrenal tissue in response to an in vitro CpG-oligodeoxynucleotide challenge in a sepsis model.<sup>12</sup>

In the present case, TLR4 was expressed in the dominant adrenal nodule, as well as in the adjacent adrenal epithelial cells that were being destroyed by autoimmune lymphocytic infiltration. In addition, test results for TLR3 were slightly positive in the inflamed adrenal cells but negative in both endothelial and inflammatory cells infiltrating the adrenal glands.

The etiologic characteristics of adrenal macronodular hyperplasia continue to be debated. It was initially proposed that this condition was caused by faulty steroidogenesis within the adrenal gland, with the corticotropin-driven compensatory adrenal hyperplasia leading to neoplastic transformation.<sup>13,14</sup> More recently, the excess cortisol secretion that is seen in most adrenal macroadenomas has been postulated to be regulated by ectopic expression of other hormones (eg, angiotensin, cate-

cholamines, serotonin, vasopressin) or by the overactive ectopic expression of several membrane-bound hormone receptors.<sup>15</sup>

The pathologic expression of TLR4 in the adrenal tumor of our patient could have been triggered by 1 of the abnormally accumulating steroid precursors if faulty steroidogenesis was the cause. Lipopolysaccharide is the normal ligand for TLR4 in dendritic cells.<sup>16</sup> However, we have previously shown that free fatty acids, such as palmitate, can induce pathologic expression of TLR4 in adipocytes.<sup>17</sup> We have also previously shown that high basal TLR3 expression and signaling are linked to high basal Wnt5a expression and signaling—and both are associated with proliferation and migration of malignant melanoma, pancreatic cancer, and papillary thyroid cancer cells.<sup>16,17</sup> The dominant adrenal nodule in our patient did not express Wnt5a and exhibited benign characteristics in hematoxylin and eosin staining, supporting our hypothesis about the trigger of the pathologic expression of TLR4 in the adrenal tumor.

It is possible that TLR4 is involved in the neoplastic transformation of adrenal tissue, similar to the role of TLR3 in other tumors.<sup>18</sup> However, we have no evidence to confirm that possibility. We suggest that the pathologic expression of TLR4 in adjacent adrenal epithelial cells functioned as antigen, presenting signals to the naïve T cells that promoted the autoimmune destruction of both adrenal glands and caused the adrenal insufficiency in our patient.

## Conclusion

We describe the first reported case, to our knowledge, of a patient with coexistent functional cortisol-secreting macronodular adrenal tumor resulting in Cushing syndrome, and immune-mediated adrenalitis resulting in Addison disease. The mechanisms for these comorbid pathologic conditions are unclear. However, the mechanisms may involve TLR expression, with faulty steroid biogenesis as a possible inducer of TLRs in adrenal tissue, ultimately leading to immune-mediated destruction of the adrenal glands.

## References

- Swain JM, Grant CS, Schlinkert RT, et al. Corticotropin-independent macronodular adrenal hyperplasia: a clinicopathologic correlation. *Arch Surg*. 1998;133(5):541-546.
- Volpé R. *Autoimmune Diseases of the Endocrine System*. Boca Raton, FL: CRC Press; 1990:299-300.
- Neufeld M, Maclaren NK, Blizzard RM. Two types of autoimmune Addison's disease associated with different polyglandular autoimmune (PGA) syndromes. *Medicine (Baltimore)*. 1981;60(5):355-362.
- Doppman JL, Miller DL, Dwyer AJ, et al. Macronodular adrenal hyperplasia in Cushing disease. *Radiology*. 1998;166(2):347-352.
- Betterle C, Volpato M, Rees Smith B, et al. Adrenal cortex and steroid 21-hydroxylase autoantibodies in adult patients with organ-specific autoimmune diseases: markers of low progression to clinical Addison's disease. *J Clin Endocrinol Metab*. 1997;82(3):932-938.
- Yu L, Brewer KW, Gates S, et al. DRB1\*04 and DQ alleles: expression of 21-hydroxylase autoantibodies and risk of progression to Addison's disease. *J Clin Endocrinol Metab*. 1999;84(1):328-335.
- Underhill DM. Toll-like receptors: networking for success. *Eur J Immunol*. 2003;33(7):1767-1775.
- Harii N, Lewis CJ, Vasko V, et al. Thyrocytes express a functional toll-like receptor 3: overexpression can be induced by viral infection and reversed by phenylmethimazole and is associated with Hashimoto's autoimmune thyroiditis [published online ahead of print January 20, 2005]. *Mol Endocrinol*. 2005;19(5):1231-1250.
- Rasschaert J, Ladriere L, Urbain M, et al. Toll-like receptor 3 and STAT-1 contribute to double-stranded RNA+ interferon-gamma-induced apoptosis in primary pancreatic beta-cells [published online ahead of print July 15, 2005]. *J Biol Chem*. 2005;280(40):33984-33991.
- McCall K, Holliday D, Kohn L, Wallace B, Schwartz F. Phenylmethimazole antagonism of toll-like receptor 4 (TLR4) signaling in 3T3L-1 adipocytes. Abstract 2013P presented at: 67th Scientific Sessions of the American Diabetes Association; June 2007; Chicago, IL.
- Christman MA II, Goetz DJ, Dickerson E, et al. Wnt5a is expressed in murine and human atherosclerotic lesions [published online ahead of print May 2, 2008]. *Am J Physiol Heart Circ Physiol*. 2008;294(6):H2864-H2870.
- Smals AG, Pieters GF, van Haelst UJ, Kloppenborg PW. Macronodular adrenocortical hyperplasia in long-standing Cushing's disease. *J Clin Endocrinol Metab*. 1984;58(1):25-31.
- Sturrock ND, Morgan L, Jeffcoate WJ. Autonomous nodular hyperplasia of the adrenal cortex: tertiary hypercortisolism? *Clin Endocrinol (Oxf)*. 1995;43(6):753-758.
- Christopoulos S, Bourdeau I, Lacroix A. Clinical and subclinical ACTH-independent macronodular adrenal hyperplasia and aberrant hormone receptors. *Horm Res*. 2005;64(3):119-131.
- Lin Y, Lee H, Berg AH, Lisanti MP, Shapiro L, Scherer PE. The lipopolysaccharide-activated toll-like receptor (TLR)-4 induces synthesis of the closely related receptor TLR-2 in adipocytes. *J Biol Chem*. 2000;275(32):24255-24263.
- McCall KD, Harii N, Lewis CJ, et al. High basal levels of functional toll-like receptor 3 (TLR3) and noncanonical Wnt5a are expressed in papillary thyroid cancer and are coordinately decreased by phenylmethimazole together with cell proliferation and migration [published online ahead of print May 24, 2007]. *Endocrinology*. 2007;148(9):4226-4237.
- Schwartz AL, Malgor R, Dickerson E, et al. Phenylmethimazole decreases toll-like receptor 3 and noncanonical Wnt5a expression in pancreatic cancer and melanoma together with tumor cell growth and migration [published online ahead of print May 26, 2009]. *Clin Cancer Res*. 2009;15(12):4114-4122.
- Kohn LD, Schwartz F, Silver MJ, Goetz DJ. Toll-like receptors in nonimmune cells and environmental induction of the pathologic expression of innate immunity and autoimmune inflammatory diseases: a new therapeutic opportunity. *Ohio Res Clin Rev*. 2004;15:3-11.