

## A Case of Idiopathic Colonic Varices

Matthew V. Speicher, OMS IV  
 Michael T. Keegan, MD  
 Kathryn E. Kirk, MD

From the Metropolitan Gastroenterology Group in Chevy Chase, Maryland.

At the time of the case, Student Doctor Speicher was a third-year osteopathic medical student at the Philadelphia College of Osteopathic Medicine in Pennsylvania.

Financial Disclosures:  
 None reported.

Address correspondence to Matthew V. Speicher, OMS IV, 4170 City Ave, Philadelphia, PA 19131-1610.

E-mail: matthewspe@pcom.edu

Submitted  
 May 14, 2013;  
 final revision received  
 July 14, 2013;  
 accepted  
 July 26, 2013

**Colonic varices, usually detected by means of colonoscopy, are extremely rare and typically indicative of portal hypertension or chronic hepatopathology. Even more rare are those cases with no underlying disease, or idiopathic colonic varices. The authors report a case of these unexplained varices found during colonoscopy of a 30-year-old man with a 10-year history of diarrhea and occasional bloody stool. A thorough workup was performed, revealing no underlying abnormalities for his varices. Additionally, the authors review the literature of this rare diagnosis. Physicians must rule out hepatic, vascular, and cardiac causes before classifying a case of varices as idiopathic.**

*J Am Osteopath Assoc.* 2014;114(1):56-59  
 doi:10.7556/jaoa.2014.008

Colonic varices are a source of rectal bleeding in which attempts should always be made to find an underlying etiologic pattern. Physicians should rule out a hepatic cause—including portal hypertension, fibrosis, cirrhosis, necrosis, and thrombosis, as well as vascular anomalies and cardiac conditions—before classifying a case of varices as idiopathic.

Idiopathic colonic varices are extremely rare, with 38 cases reported in the literature, to our knowledge.<sup>1-31</sup> Bright red blood in the rectum with or without pain is often the presenting sign. Typical etiologic factors of a colonic varix are liver disease with portal hypertension or portal or mesenteric thrombosis. Less common causes are vascular malformations, heart failure, and abdominal adhesions. When these causes have been ruled out, the colonic varices are considered idiopathic. In the present report, we describe a case of idiopathic colonic varices.

### Report of Case

A 30-year-old man presented to a community emergency department because of intense abdominal discomfort, distention, and diarrhea. His past medical history was notable for a 10-year history of chronic diarrhea, bloating, occasional bloody stool, and no family history of gastrointestinal disease or complications. A computed tomographic (CT) scan of the abdomen revealed a possible partial obstruction in the terminal ileum. The patient was discharged to home with analgesics and instructed to follow up with a gastroenterologist.

Five days later, the patient presented to our office with continued mild to moderate abdominal discomfort and diarrhea. Family history, social history, and physical examination findings were unremarkable. After a review of the CT scan, which showed

contrast material and some evidence of bowel wall thickening, an inflammatory process was suspected. Laboratory tests were ordered, and a colonoscopy was scheduled for the next day.

The colonoscopy revealed diffuse erythema and congestion in the terminal ileum and throughout the colon. Markedly dilated, tortuous veins were appreciated throughout the colon (*Figure 1*) and rectum. From biopsies obtained throughout the colon, pathologic results revealed dilated thin-walled vessels in the lamina propria with vascular congestion and hemorrhage (*Figure 2*) but did not reveal colitis. Because of the finding of varices throughout the colon, portal hypertension or liver disease was suspected.

The CT scan was reviewed again and discussed with the original reading radiologist, and it was determined that there was no sign of liver disease and that mesenteric arteries and veins appeared normal. All results from other laboratory tests, including liver enzyme levels, were also unremarkable.

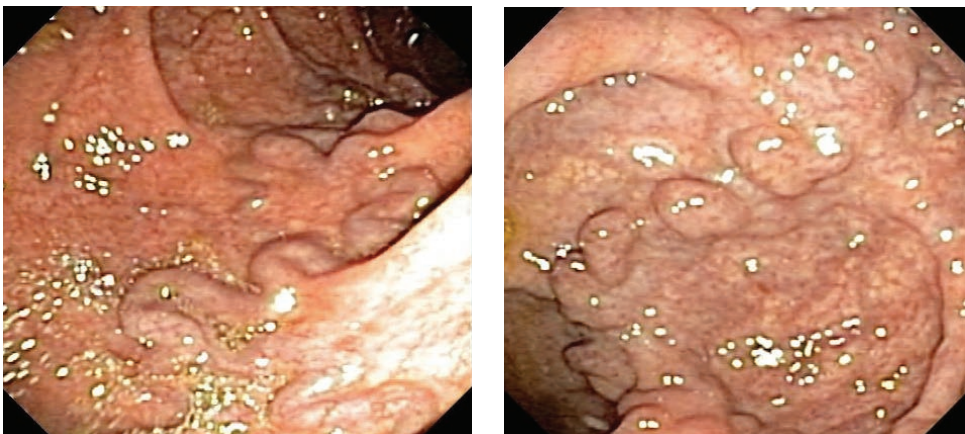
Two weeks after initial presentation, Doppler ultrasonography was performed and results revealed normal flow in the hepatic and portal veins, as well as in the inferior vena cava. Ultrasonographic image showed dif-

fusely increased echogenicity consistent with diffuse fatty change. A core liver biopsy was ordered to investigate a hepatic etiologic process in the varices.

Six weeks after initial presentation, an upper endoscopy was performed and revealed no esophageal varices or signs of venous congestion.

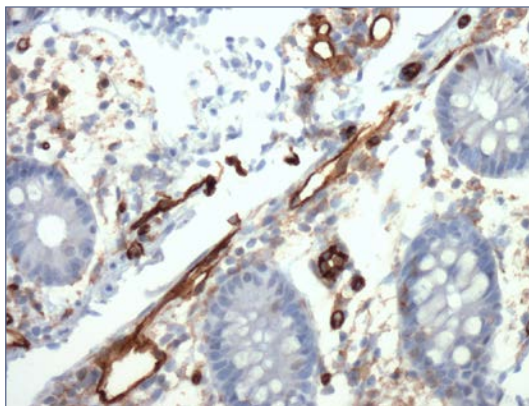
At 8 weeks from initial presentation, the core liver biopsy was performed and confirmed mild to moderate steatosis but no significant cirrhosis, necrosis, or bridging fibrosis. At the time of the biopsy, hepatic and portal vein pressure measurements were obtained and revealed a mean right atrial pressure of 10 mm Hg, a mean free hepatic vein pressure of 10 mm Hg, and a mean wedged hepatic vein pressure of 11 mm Hg. These measurements yield a hepatic vein pressure gradient of 1 mm Hg (normal, 1-5 mm Hg) and allowed us to rule out hepatic outflow obstruction and portal hypertension.

At the completion of the 8-week visit, the patient had already experienced a moderate improvement of symptoms, with 2 soft bowel movements per day and no associated pain. After an extensive workup, no clear explanation for his colonic varices emerged. We continue to follow up this patient for possible recurrence and monitor for signs of liver disease.



**Figure 1.**

Colonoscopic images of varices revealed markedly dilated, tortuous veins that were appreciated throughout the colon of a 30-year-old man with abdominal discomfort and diarrhea.



**Figure 2.**  
A 20X CD31 stain (mouse monoclonal JC/70A) of a sample taken from the colon of a 30-year-old man with abdominal discomfort and diarrhea, revealing dilated, thin-walled vessels in the lamina propria with vascular congestion and hemorrhage.

## Discussion

Even in the presence of advanced liver disease, colonic varices are relatively rare. Bresci et al<sup>32</sup> detected colonic varices in 31% of patients with cirrhosis of the liver. The prevalence of colonic varices is virtually unattainable because the condition could remain subclinical for a lifetime. In an autopsy-based study that explored the prevalence of the condition, Feldman et al<sup>33</sup> found colonic varices in 2 of 2912 cadavers (0.0007%).

Idiopathic colonic varices are extremely rare, with 38 cases to our knowledge being reported in the literature to date.<sup>1-31</sup> Age at diagnosis varied from 14 to 81 years with a mean, median, and mode of 41, 37, and 33 years, respectively. The male-to-female ratio of reported cases of idiopathic colonic varices is 25:13. Most cases presented with a history of blood in the stool. Due to the idiopathic nature of the disease and the associated blood loss, at least 13 cases required at least a partial resection of the bowel.<sup>1-13</sup> However, conservative management was deemed prudent in most cases.<sup>12,14-27</sup>

Most colonic varices of known origin were found along either the distribution of the superior or inferior mesenteric vein, but idiopathic varices tended to occur throughout the colon. Gudjonsson et al<sup>34</sup> reviewed 69

cases of colonic varices and found 66% of instances distributed along the inferior mesenteric vein, 26% along that of the superior mesenteric vein, and 8% throughout the colon. Adding in the present case, there are currently 26 of 39 cases (67%) of documented idiopathic colonic varices that involved the entire colon.<sup>1-6,10,12-19,21-23,25-30</sup>

There have been several cases of colonic varices without portal hypertension in which an alternate etiologic process was identified. Three instances of vascular malformations leading to colonic varices,<sup>35-37</sup> with 2 including a hereditary component,<sup>35,36</sup> have been documented. At least 15 cases of idiopathic colonic varices in the literature have a familial component.<sup>12,14,19,22,28,29,31</sup> Our patient, however, has no family history of gastrointestinal disease or complications.

Adhesions have been documented as a cause of colonic varices without portal hypertension,<sup>38</sup> but the varices were localized to an area of the colon in the vicinity of the site of the adhesion. The varices in our patient were throughout the colon and rectum and do not follow the localized profile that would be expected with adhesions.

Congestive heart failure has also been implicated in colonic varices.<sup>33</sup> This condition can lead to venous congestion, such as that seen in colonic varices. Nevertheless, our patient showed no signs of venous congestion anywhere else in the body and no indications of heart disease.

## Conclusion

Idiopathic colonic varices generally manifest with active, or a history of, rectal bleeding.<sup>4</sup> In cases of idiopathic colonic varices with multiple recurrences or refractory bleeding, surgical colectomy may be considered. However, in many patients, including ours, conservative management was indicated.

## References

1. Gentilli S, Aronici M, Portigliotti L, Pretato T, Garavoglia M. Idiopathic ileo-colonic varices in a young patient [published online September 11, 2011]. *Updates Surg*. 2012;64(3):235-238. doi:10.1007/s13304-011-0101-8.

2. Grasso E, Sciolli L, Ravetta F, Pelloni A. A rare case of idiopathic colonic varices: case report and review of the literature. *Chirurgia*. 2012;25(2):111-114.
3. Krishna RP, Singh RK, Ghoshal UC. Recurrent lower gastrointestinal bleeding from idiopathic ileocolonic varices: a case report. *J Med Case Rep*. 2010;4:257. doi:10.1186/1752-1947-4-257.
4. Abraham-Igwe C, Patel R. Idiopathic colonic varices: a case report. *Endoscopy*. 2002;34(8):680.
5. Lopes LM, Ramada JM, Certo MG, et al. Massive lower gastrointestinal bleeding from idiopathic ileocolonic varix: report of a case. *Dis Colon Rectum*. 2006;49(4):524-526.
6. Keren D, Rainis T, Stermer E, Goldstein O, Lavy A. Extensive idiopathic colonic varices in a young patient. *Dig Dis Sci*. 2005;50(6):1175-1176.
7. Han JH, Jeon WJ, Chae HB, et al. A case of idiopathic colonic varices: a rare cause of hematochezia misconceived as tumor. *World J Gastroenterol*. 2006;12(16):2629-2632.
8. Detry RJ, Kartheuser A, Moisse R, et al. Idiopathic non-familial rectal and colonic varices requiring sigmoidorectal resection and coloanal anastomosis [case report]. *Eur J Gastroenterol Hepatol*. 1996;8(10):1023-1026.
9. Villarreal HA, Marts BC, Longo WE, Ure T, Vernava AM, Joshi S. Congenital colonic varices in the adult: report of a case. *Dis Colon Rectum*. 1995;38(9):990-992.
10. Mehta R, Deepak S, John A, Balakrishnan V. Idiopathic colonic varices. *Indian J Gastroenterol*. 2004;23(1):30-31.
11. Isbister WH, Pease CW, Delahunt B. Colonic varices: report of a case. *Dis Colon Rectum*. 1989;32(6):524-527.
12. Hawkey CJ, Amar SS, Daintith HA, Toghil PJ. Familial varices of the colon occurring without evidence of portal hypertension. *Br J Radiol*. 1985;58(691):677-679.
13. Wagner M, Kiselow MC, Keats WL, Jan ML. Varices of the colon. *Arch Surg*. 1970;100(6):718-720.
14. Zaman L, Bebb JR, Dunlop SP, Jobling JC, Teahon K. Familial colonic varices—a cause of “polyposis” on barium enema. *Br J Radiol*. 2008;81(961):e17-e19. doi:10.1259/bjr/66055283.
15. Simvoulakis E, Viazis N, Pipis P, Stefanidis G, Avgerinos A. Diffuse idiopathic colonic varices presenting with lower gastrointestinal bleeding in an elderly patient: a case report and review of the literature. *Acta Gastroenterol Belg*. 2006;69(1):15-19.
16. Nikolopoulos N, Xynos E, Datsakis K, Kasapidis P, Vassilakis JS. Varicosis coli totalis: report of a case of idiopathic aetiology. *Digestion*. 1990;47(4):232-235.
17. Tang SJ, Zanati S, Dubcenco E, et al. Diagnosis of small-bowel varices by capsule endoscopy. *Gastrointest Endosc*. 2004;60(1):129-135.
18. Vuillemin E, Croquet V, Coumeau D, Ouali L. Idiopathic ileocolonic varices: a rare cause of lower gastrointestinal bleeding [in French]. *Gastroentérologie Clinique et Biologique*. 2004;28(11):1183-1184.
19. López-Cepero Andrada JM, López Silva M, Ferr Álamo A, Salado Fuentes M, Benítez Roldán A. Varices colónicas familiares: presentación de dos casos. *Gastroenterología y Hepatología*. 2000;23(7):341-343.
20. Place RJ. Idiopathic colonic varices as a cause of lower gastrointestinal bleeding. *South Med J*. 2000;93(11):1112-1114.
21. Van Gossum M, Reuss K, Moussaoui M, Bourgeois V. Idiopathic colonic varices: an unusual cause of massive lower gastrointestinal hemorrhage [case report]. *Acta Gastroenterol Belg*. 2000;63(4):397-399.
22. Bernardini D, Barthet M, Castellani P, Sahel J, Gauthier A, Botta-Fridlund D. Familial varices of the colon: report of four cases [in French]. *Gastroentérologie Clinique et Biologique*. 1998;22(10):827-830.
23. Schilling D, Maier M, Kohler B, Würmel W, Jakob P, Riemann JF. Idiopathic mesenteric varices causing lower gastrointestinal bleeding. *Eur J Gastroenterol Hepatol*. 1996;8(2):177-179.
24. Loffeld RJ, van Bochove A, de Graaf JC. Colonic varices: an unusual cause of occult blood loss [in Dutch]. *Nederlandsche Tijdschrift voor Geneeskunde*. 1996;140(49):2467-2469.
25. Shrestha R, Dunkelberg JC, Schaefer JW. Idiopathic colonic varices: an unusual cause of massive lower gastrointestinal hemorrhage [case report]. *Am J Gastroenterol*. 1995;90(3):496-497.
26. Vella-Camilleri FC, Friedrich R, Vento AO. Diffuse colonic varices: an uncommon cause of intestinal bleeding. *Am J Gastroenterol*. 1986;81(6):492-494.
27. Weingart J, Höchter W, Ottenjann R. Varices of the entire colon—an unusual cause of recurrent intestinal bleeding. *Endoscopy*. 1982;14(2):69-70.
28. el-Dosoky MM, Reeders JW, Dol JA, Tytgat GN. Familial intestinal varices without portal hypertension: a case report. *Eur J Radiol*. 1994;18(2):140-141.
29. Morini S, Caruso F, De Angelis P. Familial varices of the small and large bowel. *Endoscopy*. 1993;25(2):188-190.
30. Iredale JP, Ridings P, McGinn FP, Arthur MJ. Familial and idiopathic colonic varices: an unusual cause of lower gastrointestinal haemorrhage [case report]. *Gut*. 1992;33(9):1285-1288.
31. Solis-Herruzo JA. Familial varices of the colon diagnosed by colonoscopy. *Gastrointest Endosc*. 1977;24(2):85-86.
32. Bresci G, Parisi G, Capria A. Clinical relevance of colonic lesions in cirrhotic patients with portal hypertension. *Endoscopy*. 2006;38(8):830-835.
33. Feldman M Sr, Smith VM, Warner CG. Varices of the colon: report of three cases. *JAMA*. 1962;179:729-730.
34. Gudjonsson H, Zeiler D, Gamelli RL, Kaye MD. Colonic varices: report of an unusual case diagnosed by radionuclide scanning, with review of the literature. *Gastroenterology*. 1986;91(6):1543-1547.
35. Hardy M, Barbin JY, Caroli J. Familial mesenteric hypertension [in French]. *Revue Médico-chirurgicale des Maladies du Foie*. 1967;42(6):237-246.
36. Atin V, Sabas JA, Cotano JR, Madariaga M, Galan D. Familial varices of the colon and small bowel. *Int J Colorectal Dis*. 1993;8(1):4-8.
37. Sugiyama S, Yashiro K, Nagasaki K, et al. Extensive varices of ileocecum: report of a case. *Dis Colon Rectum*. 1992;35(11):1089-1091.
38. Manzi D, Samanta AK. Adhesion-related colonic varices. *J Clin Gastroenterol*. 1985;7(1):71-75.

© 2014 American Osteopathic Association