

## Achilles Tendon Disorders

Sundeep S. Saini, DO; Christopher W. Reb, DO; Megan Chapter, DO;  
and Joseph N. Daniel, DO

From the Department of Orthopedic Surgery at the Rowan University School of Osteopathic Medicine in Stratford, New Jersey (Drs Saini, Reb, and Chapter), and the Rothman Institute at Jefferson Medical College in Philadelphia, Pennsylvania (Dr Daniel).

Financial Disclosures:  
None reported.

Support: None reported.

Address correspondence to  
Joseph N. Daniel, DO,  
The Rothman Institute,  
Jefferson Medical College,  
Foot and Ankle Service,  
925 Chestnut St, 5th Floor,  
Philadelphia, PA  
19107-4206.

E-mail: joe.daniel@  
rothmaninstitute.com

Submitted  
February 16, 2015;  
revision received  
July 14, 2015; accepted  
August 7, 2015.

**Disorders of the Achilles tendon, the largest tendon in the human body, are common and occur in both active and sedentary persons. A thorough history and physical examination allow primary care physicians to make an accurate diagnosis and to initiate appropriate management. Mismanaged or neglected injuries markedly decrease a patient's quality of life. A growing body of related literature is the basis for current therapeutic regimens, which use a multimodal conservative approach, including osteopathic manipulative treatment. Although primary care physicians can manage most cases of Achilles tendon disorders, specialty care may be needed in certain instances. Procedural intervention should consider any comorbid conditions in addition to patients' lifestyle to help guide decision making. When appropriately managed, Achilles tendon disorders generally carry a favorable prognosis.**

*J Am Osteopath Assoc.* 2015;115(11):670-676  
doi:10.7556/jaoa.2015.138

**A**chilles tendon disorders afflict athletes and sedentary persons alike.<sup>1-3</sup> Among athletes, the lifetime prevalence of acute tendon rupture and chronic tendinopathy are 8.3% and 23.9%, respectively.<sup>4</sup> In the general population, these figures are 5.9% and 2.1%, respectively.<sup>4</sup> Early recognition and appropriate management are critical. Scheller et al<sup>5</sup> reported that 25% of acute Achilles tendon ruptures were missed on initial presentation. Kujala et al<sup>4</sup> reported that neglected or ineffectively managed Achilles tendon disorders may substantially diminish a patient's quality of life. Appropriately managed Achilles tendon disorders, both acute and chronic, generally carry a good prognosis.<sup>6</sup> The purpose of this evidence-based clinical review is to provide a succinct update for primary care physicians on this commonly encountered clinical problem and to underscore the efficacy of conservative treatment options, including osteopathic manipulative treatment (OMT).

### Anatomy

The Achilles tendon is the largest tendon in the human body. It forms from the confluence of the gastrocnemius and soleus muscle tendons, known as the triceps surae, which is innervated by the sacral spinal nerve 1 via the sciatic nerve 5 to 6 cm proximal to its insertion onto the posterior aspect of the calcaneal tuberosity.<sup>6</sup> The tendon is enveloped in a thin vascularized layer called the *paratenon*, which is perfused by branches from the posterior tibial and peroneal arteries. The tendon itself, however, is largely avascular, with its mid-portion having the least perfusion.<sup>7,8</sup> This lack of vascular perfusion leaves the Achilles tendon highly susceptible to injury and poorly able to heal.<sup>7</sup>

## Biomechanics

The tendon transmits the force generated from the contraction of the triceps surae muscles to the foot through the ankle joint. When standing, the soleus muscle, acting in concert with the tibialis anterior muscle, stabilizes the tibia. During locomotion, the triceps surae serves 2 functions: to eccentrically contract to control the forward progression of the tibia during the stance phase of gait, and to concentrically contract against the fixed forefoot during the terminal stance through toe-off phases of gait, thereby creating the propulsive force necessary for walking, running, and jumping.

## Clinical Evaluation

Most Achilles tendon disorders can be diagnosed on a clinical basis. A thorough problem-focused history should include details of the inciting event, the presence and duration of prodromal symptoms, the patients' customary daily activities, and the frequency and level of athletic activity, if applicable. Previous lower extremity trauma should also be noted. Given the well-described associations with Achilles tendon disorders, medical history taking should specifically address the coexistence of autoimmune disease; plantar fasciitis;

*Ineffectively managed Achilles tendon disorders may substantially diminish a patient's quality of life.*

metatarsalgia; plantar skin problems, such as callosities or ulcerations; the rate and amount of any weight gained, if applicable; previous treatments, such as injection of corticosteroids into the tendon; frequency and duration of systemic fluoroquinolone antibiotics, if applicable; and smoking history.<sup>9-11</sup>

Patients with acute ruptures typically report that the sudden onset of posterior heel pain occurred during high-impact activity.<sup>19</sup> Chronic conditions develop more in-

### KEY POINTS

Primary care physicians commonly see a variety of Achilles tendon disorders in active and sedentary patients alike.

A thorough history and physical examination are the most important steps to differentiating among Achilles tendon disorders.

Diagnostic imaging of Achilles tendon disorders is typically reserved for refractory cases but may be appropriate at any time to rule out other items in the differential diagnosis or when surgical intervention is to be considered.

Most Achilles tendon disorders will improve with conservative management consisting of activity modification, osteopathic manipulative treatment, physical therapy, cryotherapy, and targeted exercises.

Operative management of Achilles tendon disorders is indicated in patients with high functional demands or after 6 months of failed conservative therapy.

sidiously, often after an abrupt increase in activity level or training intensity, particularly among middle-aged persons or seemingly without provocation among sedentary and elderly persons.<sup>12,13</sup>

Given the broad spectrum of disorders that may present similarly to Achilles tendon disorders, a detailed musculoskeletal examination of both lower extremities should always be performed simultaneously. The skin over the heel cord should be inspected for swelling, ecchymosis, or bony prominences. The entire length of the tendon should then be palpated to feel for fullness, irregularity, gapping, or tenderness. Active and passive ankle ranges of motion should be assessed and muscle strength testing performed. Gait disturbances should be observed with the patient walking barefoot. The examination should be broadened to include the upper extremities and autonomic nervous systems as needed. The *Table* summarizes the distinguishing patient history and physical examination findings among the various Achilles tendon disorders.

A logical role exists for OMT during the evaluation for Achilles tendon disorder. By reducing or eliminating the effects of somatic dysfunction on the pa-

**Table.**  
**Characteristics, Examination, and Management of Achilles Tendon Pain<sup>6,9,14-25</sup>**

Diagnosis	Pathophysiologic Characteristics	History	Physical Examination Findings	Diagnostic Imaging	Conservative Management
Acute Achilles rupture	Sudden rupture at the midportion	Sudden posterior ankle pain often accompanied by an audible “pop”; most common in athletes	Diffuse pain; swelling; ecchymosis over Achilles tendon; decreased plantar flexion strength; palpable tendinous defect; positive Thompson test result	MRI or US	Ice therapy; leg elevation; cast immobilization in 15°-20° plantar flexion; no weight bearing
Chronic Achilles rupture	Rupture 4-6 wk after injury	Vague posterior heel pain onset few weeks before; weakened push off during gait; difficulty climbing stairs	Tenderness over Achilles tendon; decreased plantar flexion strength; increased passive dorsiflexion; positive Thompson test result	MRI or US	Ice therapy; cast immobilization in 15°-20° plantar flexion; no weight bearing
Insertional Achilles tendinosis	Degenerative process at the calcaneal insertion	Posterior heel pain worsened on rising or after rest	Swelling along tendon; pain with palpation at calcaneal insertion; posterior heel spur (Haglund deformity)	Not recommended <sup>a</sup>	Ice therapy; activity modification; heel lifts or orthoses
Noninsertional Achilles tendinosis	Intratendinous degeneration	Pain at start and end of physical activities; less discomfort between activities	Pain on palpation of midtendon; tenderness with plantar flexion and dorsiflexion	Not recommended <sup>a</sup>	Ice therapy; activity modification; NSAIDs; eccentric stretching exercises
Retrocalcaneal bursitis	Chronic inflammation of the retrocalcaneal bursa	Posterior heel pain with sudden increase in activity; pain while walking or rising on toes	Pain on palpation anterior to Achilles insertion; direct simultaneous pressure to the medial and lateral borders of tendon	Not recommended <sup>a</sup>	Ice therapy; activity modification; NSAIDs
Paratenonitis	Degeneration of vascular paratenon surrounding Achilles tendon	Mild, dull pain at rest that worsens with activity; common in professional dancers and long-distance runners	Tenderness along Achilles tendon; pain with resisted plantar flexion	Not recommended <sup>a</sup>	Ice therapy; activity modification; NSAIDs; physical therapy

<sup>a</sup> Plain radiographs and MRI may rule out other injuries.

**Abbreviations:** MRI, magnetic resonance imaging; NSAID, nonsteroidal anti-inflammatory drug; US, ultrasonography.

tient’s symptoms, the physician may obtain a clearer assessment of the patient’s problem.

After a thorough clinical evaluation has ruled out the Achilles tendon as the primary source of pain, a more inclusive differential diagnosis should be considered (*Figure 1*). The differential diagnosis can be classified into vascular, neurogenic, myotendinous, and osseous origins.

### Diagnostic Imaging

The initial evaluation of Achilles tendon disorders does not often require the use of diagnostic imaging. However, magnetic resonance imaging, ultrasonography, and radiographic imaging may be necessary in the presence of equivocal examination findings, to narrow the differential diagnosis, or for surgical planning.

## Conservative Management

Most Achilles tendon disorders can be successfully managed conservatively. Because older and sedentary patients with multiple comorbidities have higher rates of postoperative complications,<sup>20,26</sup> conservative management should

*Achilles tendon overuse injuries are initially managed with rest, ice, activity modification, and symptomatic analgesia.*

be the primary consideration in these patients. Poor surgical candidates or those with low functional demand should also be treated with conservative measures.<sup>27,28</sup> Achilles tendon overuse injuries are initially managed with rest, ice, activity modification, and symptomatic analgesia (eg, nonsteroidal anti-inflammatory drugs).<sup>6,12,17,23</sup>

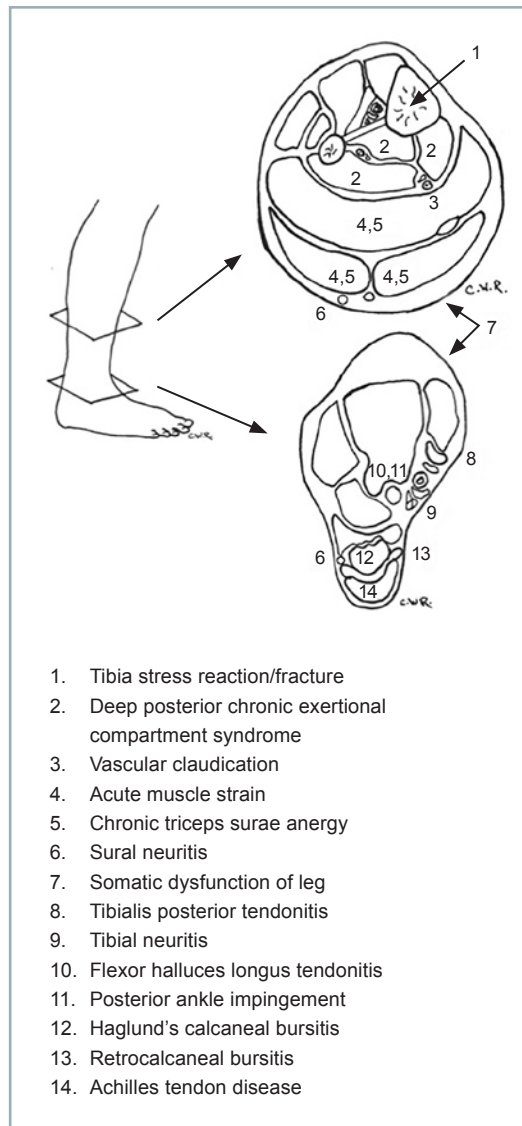
### Orthoses

Acute ruptures may be managed initially with an Achilles walking boot beginning at 20° of ankle-plantar flexion. The ankle is repositioned back to neutral in a stepwise fashion at 6 to 8 weeks.<sup>29</sup> Full weight bearing in this orthosis may resume after 2 to 3 weeks.

Long-term use of a brace or an ankle-foot orthosis may be needed to provide sufficient functional stability.<sup>30</sup> Tendinosis (both insertional and noninsertional) and paratenonitis may respond to foot orthoses, such as cushioned heel lifts, which function by correcting overpronation and elevating the heel to decrease tendon irritation, and stretching.<sup>17</sup> If symptoms do not improve, a physical therapy regimen focusing on eccentric stretching exercises may be considered.

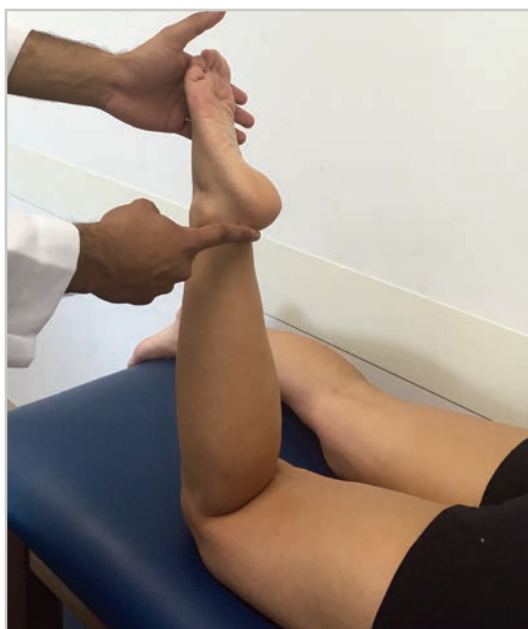### OMT

The utility of OMT in managing Achilles tendon disorders is understudied. However, the counterstrain technique has been shown to alleviate excess tension placed on the Achilles tendon, thereby decreasing nociceptor



**Figure 1.** Differential diagnosis by area of Achilles tendon pain.

activity.<sup>31</sup> This method involves placing the Achilles tendon in the position of least resistance by having the patient lay prone while passively flexing the knee and plantar flexing the foot and ankle (Figure 2). This position should be maintained for approximately 90 seconds while monitoring the tenderpoint, most commonly lo-



**Figure 2.** Achilles tendon counterstrain technique. As the patient lies prone, the physician places the Achilles tendon in the position of least resistance with passive flexing of the knee and plantar flexing of the foot and ankle. This position is maintained for 90 seconds while the physician monitors the tender point, most commonly located along the tendon or at its point of insertion. The foot is then placed in a neutral position and reassessed.

cated along the tendon or at its point of insertion. The foot should then be placed in a neutral position and reassessed.<sup>31</sup>

### **Eccentric Stretching**

To counteract the failed healing response to repetitive subfailure loading, eccentric stretching has been proposed to facilitate collagen fiber cross-linking and promote tendon remodeling.<sup>13,32</sup> This method is especially effective in cases of paratenonitis and noninsertional Achilles tendinosis.<sup>6,13,18</sup> Further investigation is necessary into the use of modified eccentric exercises in patients with insertional tendinosis, as these exercises seem to be beneficial in 32% of cases.<sup>12</sup>

### **Physical Therapy**

As soon as possible after the initial injury, physical therapy should be started. The therapist should initially concentrate on isometric strengthening and eventually progress to range of motion exercises for the ankle and concentric triceps surae strengthening.<sup>29,33</sup>

### **Medications and Injections**

Symptomatic analgesia is typically managed with nonsteroidal anti-inflammatory drugs.<sup>6,12,17,23</sup> Short-term anticoagulation with low-dose aspirin can be considered to prevent the formation of deep vein thrombosis.<sup>34</sup> Injections of agents, such as isotonic sodium chloride solution, local anesthetic, platelet rich plasma, and corticosteroid preparations in and around the Achilles tendon are controversial. None of these treatments has been shown to have medium- to long-term efficacy. However, clear agreement exists in the literature that corticosteroid injections should be avoided because of the increased risk of tendon rupture.<sup>12,13,18</sup> The short-term efficacy of bupivacaine or saline in conjunction with physical therapy to break up adhesions is best supported in cases of paratenonitis.<sup>6</sup>

### **Surgical Management**

Chronic Achilles tendon ruptures often require surgical reconstruction because of persistent impairment associated with nonoperative management. Referral to a specialist is indicated for acute tears in younger, active individuals with

---

*Chronic Achilles tendon ruptures often require surgical reconstruction because of persistent impairment associated with nonoperative management.*

---

higher functional demands, when a chronic tear is suspected, or at any time when Achilles overuse symptoms are progressive, persist, or recur despite approximately 6 months of conservative management.

**TAKE-HOME POINTS**

Detailed History and Physical Examination
Achilles tendon rupture
Initial management: ice, cast immobilization, and non-weight-bearing status
Physical therapy: start within a few days of initial injury
Specialty referral: young, active patients or patients with chronic ruptures
Achilles tendon overuse injuries
Initial management: ice, rest, activity modification, NSAIDs, and orthoses
Pain relief: OMT, physical therapy, and judicious use of injections
Specialty referral: failure of conservative management after 6 months of progressive symptoms

**Summary**

Achilles tendon injuries are among the most common musculoskeletal injuries.<sup>6</sup> The diagnosis of these injuries is most commonly based on a thorough history and physical examination and may require imaging in certain cases. Acute tendon ruptures should always be ruled out at initial presentation. Risk factors include autoimmune disease, plantar fasciitis, obesity, fluoroquinolone use, local corticosteroid injection, and tobacco use. Conservative management modalities are successful in most cases of Achilles tendon disorders.<sup>6</sup> Whereas Achilles overuse injuries are primarily managed with rest, ice, activity modification, and nonsteroidal anti-inflammatory drugs, other disorders may benefit from orthoses, OMT, eccentric stretching exercises, physical therapy, medications, and various injections. Surgical intervention should be reserved for acute tears in younger patients, active patients, patients in whom a chronic tear is suspected, or those with overuse symptoms recalcitrant to conservative management.

**References**

- Suchak AA, Bostick G, Reid D, Blitz S, Jomha N. The incidence of Achilles tendon ruptures in Edmonton, Canada. *Foot Ankle Int.* 2005;26(11):932-936.
- Huttunen TT, Kannus P, Rolf C, Felländer-Tsai L, Mattila VM. Acute achilles tendon ruptures: incidence of injury and surgery in Sweden between 2001 and 2012. *Am J Sports Med.* 2014;42(10):2419-2423. doi:10.1177/0363546514540599.
- Alfredson H, Lorentzon R. Chronic Achilles tendinosis: recommendations for treatment and prevention. *Sports Med.* 2000;29(2):135-146.
- Kujala UM, Sarna S, Kaprio J. Cumulative incidence of achilles tendon rupture and tendinopathy in male former elite athletes. *Clin J Sport Med.* 2005;15(3):133-135.
- Scheller AD, Kasser JR, Quigley TB. Tendon injuries about the ankle. *Orthop Clin North Am.* 1980;11(4):801-811.
- Schepesis AA, Jones H, Haas AL. Current concepts: Achilles tendon disorders in athletes. *Am J Sports Med.* 2002;30(2):287-305.
- Chen TM, Rozen WM, Pan WR, Ashton MW, Richardson MD, Taylor GI. The arterial anatomy of the Achilles tendon: anatomical study and clinical implications. *Clin Anat.* 2009;22(3):377-385. doi:10.1002/ca.20758.
- Ahmed IM, Lagopoulos M, Mcconnell P, Soames RW, Sefton GK. Blood supply of the Achilles tendon. *J Orthop Res.* 1998;16(5):591-596.
- Maffulli N. Current concepts review: rupture of the Achilles tendon. *J Bone Joint Surg Am.* 1999;81(7):1019-1036.
- Hugate R, Pennypacker J, Saunders M, Juliano P. The effects of intratendinous and retrocalcaneal intrabursal injections of corticosteroid on the biomechanical properties of rabbit Achilles tendons. *J Bone Joint Surg Am.* 2004;86(4):794-801.
- Stephenson AL, Wu W, Cortes D, Rochon PA. Tendon injury and fluoroquinolone use: a systematic review. *Drug Saf.* 2013;36(9):709-721.
- Heckman DS, Gluck GS, Parekh SG. Tendon disorders of the foot and ankle, part 2: Achilles tendon disorders [review]. *Am J Sports Med.* 2009;37(6):1223-1234. doi:10.1177/0363546508331206.
- Longo UG, Ronga M, Maffulli N. Achilles tendinopathy [review]. *Sports Med Arthrosc.* 2009;17(2):112-126. doi:10.1097/JSA.0b013e3181a3d625.
- Maffulli N, Testa V, Capasso G, Sullo A. Calcific insertional Achilles tendinopathy: reattachment with bone anchors. *Am J Sports Med.* 2004;32(1):174-182.
- Weinfeld SB. Achilles tendon disorders. *Med Clin North Am.* 2014;98(2):331-338. doi:10.1016/j.mcna.2013.11.005.
- Sundararajan PP, Wilde TS. Radiographic, clinical, and magnetic resonance imaging analysis of insertional Achilles tendinopathy. *J Foot Ankle Surg.* 2014;53(2):147-151. doi:10.1053/j.jfas.2013.12.009.
- McGarvey WC, Palumbo RC, Baxter DE, Leibman BD. Insertional Achilles tendinosis: surgical treatment through a central tendon splitting approach. *Foot Ankle Int.* 2002; 23(1):19-25.

18. Magnussen RA, Dunn WR, Thomson AB. Nonoperative treatment of midportion Achilles tendinopathy: a systemic review. *Clin J Sport Med*. 2009;19(1):54-56. doi:10.1097/JSM.0b013e31818ef090.
19. Maffulli N, Ajs A. Current concepts review: management of chronic ruptures of the Achilles tendon. *J Bone Joint Surg Am*. 2008;90(6):1348-1360.
20. American Academy of Orthopaedic Surgeons. *Clinical Practice Guideline on the Diagnosis and Treatment of Acute Achilles Tendon Rupture*. Rosemont, IL: American Academy of Orthopaedic Surgeons; 2010.
21. Bevilacqua NJ. Treatment of the neglected Achilles tendon rupture. *Clin Podiatr Med Surg*. 2012;29(2):291-299.
22. Kuwada GT. An update on repair of Achilles tendon rupture: acute and delayed. *J Am Podiatr Med Assoc*. 1999;89(6):302-306.
23. Heneghan MA, Wallace T. Heel pain due to retrocalcaneal bursitis-radiographic diagnosis (with an historical footnote on Sever's disease). *Pediatr Radiol*. 1985;15(2):119-122.
24. Stephens MM. Haglund's deformity and retrocalcaneal bursitis. *Orthop Clin North Am*. 1994;25(1):41-46.
25. Kvist MH, Lehto MU, Jozsa L, Jarvinen M, Kvist HT. Chronic Achilles paratenonitis: an immunohistologic study of fibronectin and fibrinogen. *Am J Sports Med*. 1988;16(6):616-623.
26. Khan RJ, Fick D, Keogh A, Crawford J, Brammar T, Parker M. Treatment of acute achilles tendon ruptures: a meta-analysis of randomized, controlled trials. *J Bone Joint Surg Am*. 2005;87(10):2202-2210.
27. Christensen I. Rupture of the Achilles tendon; analysis of 57 cases. *Acta Chir Scand*. 1953;106(1):50-60.
28. Padanilam TG. Chronic Achilles tendon ruptures. *Foot Ankle Clin*. 2009;14(4):711-728. doi:10.1016/j.fcl.2009.08.001.
29. Weber M, Niemann M, Lanz R, Müller T. Nonoperative treatment of acute rupture of the Achilles tendon: results of a new protocol and comparison with operative treatment. *Am J Sports Med*. 2003;31(5):685-691.
30. Myerson MS. Achilles tendon ruptures. *Instr Course Lect*. 1999;48:219-230.
31. Howell JN, Cabell KS, Chila AG, Eland DC. Stretch reflex and Hoffmann reflex responses to osteopathic manipulative treatment in subjects with Achilles tendinitis. *J Am Osteopath Assoc*. 2006;106(9):537-545.
32. Mafi N, Lorentzon R, Alfredson H. Superior short-term results with eccentric calf muscle training compared to concentric training in a randomized prospective multicenter study on patients with chronic Achilles tendinosis. *Knee Surg Sports Traumatol Arthrosc*. 2001;9(1):42-47.
33. Costa ML, Macmillan K, Halliday D, et al. Randomised controlled trials of immediate weight-bearing mobilisation for rupture of the tendo Achillis. *J Bone Joint Surg Br*. 2006;88(1):69-77.
34. Makhdom AM, Cota A, Saran N, Chaytor R. Incidence of symptomatic deep venous thrombosis after Achilles tendon rupture. *J Foot Ankle Surg*. 2013;52(5):584-587. doi:10.1053/j.jfas.2013.03.001.

© 2015 American Osteopathic Association

## JAOA Submissions: Online-Only Content

The Journal of the American Osteopathic Association encourages authors to include additional online-only content (eg, videos, slides) with their manuscript submissions. Contact staff at [jaoa@osteopathic.org](mailto:jaoa@osteopathic.org) for more information.