

Feasibility of Using Ultrasonography to Establish Relationships Among Sacral Base Position, Sacral Sulcus Depth, Body Mass Index, and Sex

Michael D. Lockwood, DO
Tatyana Kondrashova, MD, PhD
Jane C. Johnson, MA

From the Department of Osteopathic Manipulative Medicine (Dr Lockwood); the Department of Family Medicine, Preventive Medicine, and Community Health (Dr Kondrashova); and the A.T. Still Research Institute (Ms Johnson) at the A.T. Still University–Kirksville College of Osteopathic Medicine in Missouri. Dr Lockwood is currently affiliated with the Department of Osteopathic Manipulative Medicine at the Liberty University College of Osteopathic Medicine in Lynchburg, Virginia.

Financial Disclosures:
None reported.

Support: None reported.

Address correspondence to Tatyana Kondrashova, MD, PhD, 800 W Jefferson St, Kirksville, MO, 63501-1443.

E-mail:
tkondrashova@atsu.edu

Submitted
April 24, 2015; revision
received June 17, 2015;
accepted July 14, 2015.

Context: Identifying relationships among anatomical structures is key in diagnosing somatic dysfunction. Ultrasonography can be used to visualize anatomical structures, identify sacroiliac landmarks, and validate anatomical findings and measurements in relation to somatic dysfunction. As part of the osteopathic manipulative medicine course at A.T. Still University–Kirksville College of Osteopathic Medicine, first-year students are trained to use ultrasonography to establish relationships among musculoskeletal structures.

Objectives: To determine the ability of first-year osteopathic medical students to establish sacral base position (SBP) and sacral sulcus depth (SSD) using ultrasonography and to identify the relationship of SBP and SSD to body mass index (BMI) and sex.

Methods: Students used ultrasonography to obtain the distance between the skin and the sacral base (the SBP) and the distance between the skin and the tip of the posterior superior iliac spine bilaterally. Next, students calculated the SSD (the distance between the tip of the posterior superior iliac spine and the SBP). Data were analyzed with respect to side of the body, BMI, sex, and age. The BMI data were subdivided into normal (18-25 mg/kg) and overweight (25-30 mg/kg) groups.

Results: Ultrasound images of 211 students were included in the study. The SBP was not significantly different between the left and right sides (36.5 mm vs 36.5 mm; $P=.95$) but was significantly different between normal and overweight BMI categories (33.0 mm vs 40.0 mm; $P<.001$) and between men and women (34.1 mm vs 39.0 mm; $P<.001$). The SSD was not significantly different between left and right sides (18.9 mm vs 19.8 mm; $P=.08$), normal and overweight BMI categories (18.9 mm vs 19.7 mm, $P=.21$), or men and women (19.7 mm vs 19.0 mm; $P=.24$). No significant relationship was identified between age and SBP ($P=.46$) or SSD ($P=.39$); however, the age range was narrow (21-33 years).

Conclusion: The study yielded repeatable and reproducible results when establishing SBP and SSD using ultrasonography. The statistically significant relationship between SBP and higher BMI and between SBP and female sex may point to more soft tissue overlaying the sacrum in these groups. Further research is needed on the use of ultrasonography to establish criteria for somatic dysfunction.

J Am Osteopath Assoc. 2015;115(11):648-653
doi:10.7556/jaoa.2015.135

Low back pain and pain involving the posterior iliac joint are common problems that most people experience at some point in their life, with the highest incidence in the third decade, although the overall prevalence increases with age.¹ A study evaluating sacroiliac joint abnormalities in a patient population with primarily low back pain found that 31.7% of patients showed sacroiliac joint abnormalities.² Despite being identified as a source of low back and lower extremity pain, sacroiliac joint pain is frequently misdiagnosed.³ Currently, no definitive physical, radiologic, or patient history findings exist that can be used to diagnose sacroiliac joint pain. In one study,⁴ the lumbar spine and pelvis were clinically assessed to understand the bony pelvic anatomical landmark asymmetry in the lumbar-pelvic region. Another study⁵ showed that accurate identification of lumbar spinous processes using multiple landmarks was dependent on examiner experience, the presence of anatomical anomalies, and participant characteristics, such as the presence of a 12th rib, body mass index (BMI), and sex. Understanding pelvic anatomical landmarks is also important in osteopathic medical education. Concepts of asymmetry in the lumbar spine and pelvis are often taught as basic facts, with little discussion of validity or reliability, but growing evidence suggests that some of these concepts are invalid or incompletely understood.⁶⁻¹⁰

Ultrasound imaging is becoming more widely used by physicians for procedural guidance, diagnostic assessment, and screening.¹¹ One study¹² compared clinical and radiologic evaluation of the sacroiliac joint with ultrasonography in patients with a recent diagnosis of spondyloarthritis. The authors found that ultrasound imaging was a promising method to study the articular and soft tissues of the sacroiliac joint, independent of clinical and radiographic examination.¹² Ultrasonography has also been used successfully to assess the posterior ligaments of the sacroiliac joint, which have been identified as a potential source of nonspecific low back pain or peripartum pelvic pain.¹³ Findings from these studies^{12,13} document the sonographic appearance,

length, and thickness of the long posterior sacroiliac ligament, which could provide useful normative data for its pathology, particularly in patients with pregnancy-related pelvic girdle pain.

Studies have demonstrated the effectiveness of incorporating ultrasonography in the medical school classroom.^{6,7} Second-year medical students improved their accuracy of measuring internal organs using ultrasonography.⁹ Other studies have demonstrated that ultrasonography is a skill that first-year medical students can master with appropriate training.^{10,14} The incorporation of ultrasonography in first-year osteopathic manipulative medicine courses has been suggested to increase students' confidence in palpatory skills in relation to somatic dysfunction and to give students a clinically advantageous skillset in image acquisition and interpretation.¹⁵

Asymmetry of body landmarks is one of the features of somatic dysfunction.¹⁶ In a study by Shaw et al,¹⁷ differences in asymmetry of the lumbar spine transverse processes were measured using musculoskeletal ultrasound imaging before and after osteopathic manipulative treatment. To date, minimal osteopathic medical research has been conducted on imaging methods to assess the relationship among body landmarks.

With the increasing need for an evidence base in the medical professions, the objective understanding of palpatory assessment methods is especially important for future osteopathic physicians.¹⁵ Ultrasonography can be used to visualize anatomical structures, identify sacroiliac landmarks, and validate anatomical findings and measurements in relation to somatic dysfunction. The purpose of the current study was to determine the ability of first-year osteopathic medical students to establish sacral base position (SBP) and sacral sulcus depth (SSD) using ultrasonography and to identify the relationships that SBP and SSD have with BMI and sex. We hypothesized that students would acquire repeatable and reproducible results when measuring SBP and SSD using ultrasonography and that these values could be used to infer relationships that SBP and SSD have with BMI and with sex.

Methods

The local institutional review board granted exempt status for the current study. Data were collected at the A. T. Still University–Kirksville College of Osteopathic Medicine in Missouri during academic years 2012–2013 and 2013–2014 on first-year osteopathic medical students' ultrasonography performance. All students participated, but those older than 33 years or with a BMI greater than 30 were excluded from the data analysis because insufficient numbers in these student populations were available to generate any meaningful conclusions or trends. The group was not randomly selected, and it represented well-functioning adults in the given age range.

Ultrasonography Assignment

The osteopathic manipulative medicine course required for first- and second-year students integrates ultrasonography assignments in which students investigate anatomical landmarks. In the current study, the assignment required students to obtain ultrasound images from each other, identify target structures, and acquire images, which they saved on an external memory card during the allotted scanning time (30 minutes per student). The assignment was preceded by a live demonstration of the scanning technique and a PowerPoint (Microsoft) presentation that explained the objectives and clinical relevance of the exercise. Students were given written instructions, and additional instruction was provided during the allotted scanning time. Each student was then required to submit his or her images electronically through a learning management system.

Students used portable ultrasonography machines with curvilinear C5-2s probes on a musculoskeletal sacral preset with a working frequency of 5 MHz. The gain and depth were adjusted individually.

Students were instructed to locate the spinous process of L5 and identify the posterior superior iliac spine (PSIS) directly lateral to the spinous process of L5. They then measured the SBP (the distances be-

tween the skin and the sacral base) and the distances between the skin and the tip of the PSIS. Next, students calculated the SSD (the distance between the tip of the PSIS and the SBP) (*Figure*). In other words, $SSD = (\text{distance from the skin to the PSIS}) - (SBP)$. The student scanners also recorded the BMI, sex, and age of the student being scanned. Students were not categorized as having present or past, acute or chronic musculoskeletal lumbar or sacral problems, injuries, or anomalies. No prescreening was performed.

Data Analysis

The amount of asymmetry for SBP and SSD between the left and right sides was calculated as the absolute value of the difference between the 2 sides. The distances for SBP and SSD as well as the asymmetry were reported in millimeters as mean (95% CI). General linear mixed models were fit to the data to determine whether each side, BMI, sex, and age were related to SBP and SSD, where side was a within-participant factor and BMI, sex, and age were between-participant factors. Body mass index was subdivided into normal (18–25) or overweight (26–30). SAS statistical software, version 9.3 (SAS Institute, Inc) was used to analyze the data. $P < .05$ was considered statistically significant.

Results

Ultrasound images were successfully obtained by 225 first-year osteopathic medical students for the sacral landmarks assignment, and images of 211 students who met the inclusion criteria were used for analysis. The majority of students were men (123 [58%]) and had a normal BMI (131 [62%]). The mean (SD) age of students was 25.5 (2.5) years, with an age range of 21 to 33 years.

The SBP was not significantly different between the left and right sides ($P = .95$; *Table*). The mean (95% CI) asymmetry in SBP was 4.2 (3.7–4.6) mm. For SBP, no significant interaction was found between BMI category

and sex ($P=.48$). The SBP was significantly different between BMI categories (mean [95% CI] normal, 33.0 [32.0-34.0] mm; overweight, 40.0 [38.6-41.4] mm; $P<.001$) and between men and women (mean [95% CI] male, 34.1 [33.1-35.1] mm; female, 39.0 [37.6-40.3] mm; $P<.001$). Age was not significantly related to SBP ($P=.46$).

The SSD was not significantly different between the left and right sides ($P=.08$). The mean (95% CI) asymmetry in SSD was 4.1 (3.6-4.6) mm. The interaction of BMI category and sex was not significant ($P=.40$). The SSD was not significantly different between BMI categories ($P=.21$) or between men and women ($P=.24$). Age was not significantly related to SSD ($P=.39$).

Discussion

The current study found statistically significant relationships between SBP and overweight and female students. This finding may reflect that more soft tissue overlays the sacrum in these groups. The clinical relevance of these findings may relate to multiple pain and disability issues, such as sacroiliac joint dysfunction, low back and pelvic-related pain, postural-related disabilities, and autonomic and lymphatic-related problems. Recognizing relationships, spatial orientation, and 3-dimensionality of body landmarks, which is important for identifying somatic dysfunction, is challenging for many students.⁵ The novice student often has difficulty palpating bony landmarks and anatomic structures to form a diagnosis of somatic dysfunction because palpatory accuracy is dependent on examiner experience.⁵ The measurement of depths of structures using ultrasound imaging provides feedback to students about the accuracy of their perceived measurements.¹⁸ Furthermore, these measurements may be used to obtain normative values for musculoskeletal structures like the sacroiliac joint to identify trends, such as the association between BMI and sacral landmarks.

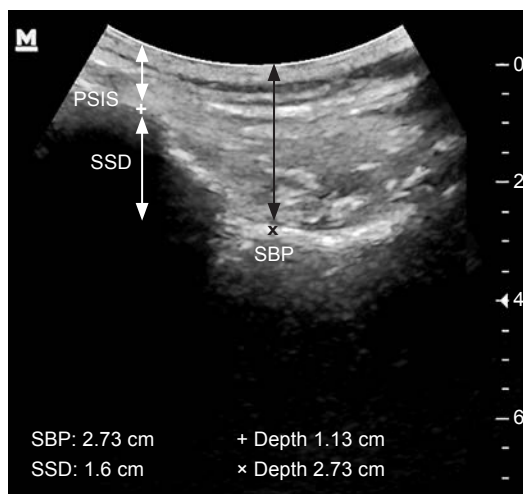


Figure.

Sacral landmarks in an ultrasound image of the left side of a 23-year-old man. The posterior superior iliac spine (PSIS) is indicated by the plus sign, and the sacral base position (SBP) by the multiplication sign. *Abbreviation:* SSD, sacral sulcus depth.

Although authors¹⁹⁻²² have described patterns of static landmarks and motion characteristics for the diagnosis of somatic dysfunction of the sacrum differently, most agree that patterns are generated about an oblique axis, vertical axis, horizontal axis, and a proposed anteroposterior axis. The nomenclature and criteria for these axes are specified in the *Glossary of Osteopathic Terminology*.²³ Somatic dysfunctions with an oblique axis and a vertical axis result in asymmetry of the left SBP and SSD compared with the right side.¹⁹⁻²¹ Dysfunctions about an axis are termed *rotations* and *torsions*, and those about a vertical axis may relate to the left or right posterior margin. Dysfunctions with multiplane asymmetry include the unilateral flexion and extension patterns. Those that occur about the horizontal axis are termed *bilateral flexion* or *bilateral extension*. Nicholas and Nicholas²¹ used an algorithm method based on the backward bending test and the relative anterior position of the right SBP to the left SBP when determining a diagnosis of somatic dysfunction.

Table.
Effect of Side, BMI, and Sex on Sacral Base Position and Sacral Sulcus Depth as Measured by Ultrasonography (N=211)

Category	n	Sacral Base Position, mm, Mean (95% CI)	Sacral Sulcus Depth, mm, Mean (95% CI)
Side			
Left	211	36.5 (35.4-37.7)	18.9 (18.0-19.7)
Right	211	36.5 (35.4-37.6)	19.8 (19.0-20.6)
<i>P</i> value ^a		.95	.08
BMI			
Normal	131	33.0 (32.0-34.0)	18.9 (18.2-19.6)
Overweight	80	40.0 (38.6-41.4)	19.7 (18.7-20.7)
<i>P</i> value ^a		<.001	.21
Sex			
Male	123	34.1 (33.1-35.1)	19.7 (19.0-20.4)
Female	88	39.0 (37.6-40.3)	19.0 (18.0-19.9)
<i>P</i> value ^a		<.001	.24

^a *P* value from general linear mixed model comparing categories.

Abbreviation: BMI, body mass index.

tion of the sacrum. Because most of the students were able to accurately identify and measure specific anatomical landmarks using ultrasonography, this imaging technology may be a useful diagnostic aid in patients with somatic dysfunction.

Results from the sacral landmarks assignment of the current study may be useful for establishing normative values for SBP and SSD and their relationship to BMI and sex. This educational assignment allowed students to develop critical thinking and data analysis skills for the future practice of evidence-based medicine, especially in relation to investigating somatic dysfunction and to acquisition and interpretation of musculoskeletal ultrasound images.

The current study had several limitations. First, it was conducted at a single institution. This limitation was difficult to avoid because few osteopathic medical

schools have integrated ultrasonography into curricula. Second, no control group was used for comparison because all of the students were required to complete the sacral landmarks assignment. Third, because no inter-examiner studies or repeated measurements were performed, we could not describe this dataset as normative data. Last, our only exclusion criteria were age and BMI. We did not group students on the basis of their medical history, and no prescreening was performed. Because of the nature of this feasibility study, in which osteopathic medical students made up the study sample, this limitation was difficult to avoid. The overwhelming majority of students were healthy, and the statistical power needed to infer any conclusions on the basis of an existing or preexisting medical condition would require a much larger sample.

Conclusion

Our study yielded repeatable and reproducible results establishing SBP and SSD using ultrasonography. First-year osteopathic medical students with higher BMI and women had significantly larger SBPs. However, more data from a larger and more diverse population are necessary to confirm the perceived depths and positions of anatomic structures that are critical for the diagnosis of patterns of somatic dysfunction of the sacrum and pelvis. Studies using ultrasound imaging to establish criteria for somatic dysfunction may be beneficial for the treatment of patients presenting with functional problems related to the sacrum and associated structures.

Author Contributions

All authors provided substantial contributions to conception and design, acquisition of data, or analysis and interpretation of data; all authors drafted the article or revised it critically for important intellectual content; all authors gave final approval of the version of the article to be published; and all authors agreed to be accountable for all aspects of the work in ensuring that questions related to the accuracy or integrity of any part of the work are appropriately investigated and resolved.

References

1. Hoy D, Brooks P, Blyth F, Buchbinder R. The Epidemiology of low back pain. *Best Pract Res Clin Rheumatol*. 2010;24(6):769-81. doi:10.1016/j.berh.2010.10.002.
2. Le Goff B, Berthelot JM, Maugars Y. Ultrasound assessment of the posterior sacroiliac ligaments. *Clin Exp Rheumatol*. 2011;29(6):1014-1017.
3. Forst SL, Wheeler MT, Fortin JD, Vilenky JA. The sacroiliac joint: anatomy, physiology and clinical significance. *Pain Physician*. 2006;9(1):61-67.
4. Knobe M, Munker R, Sellei RM, et al. Peer teaching: a randomised controlled trial using student-teachers to teach musculoskeletal ultrasound. *Med Educ*. 2010;44(2):148-155. doi:10.1111/j.1365-2923.2009.03557.x.
5. Snider KT, Snider EJ, Degenhardt BF, Johnson JC, Kribs JW. Palpatory accuracy of lumbar spinous processes using multiple bony landmarks. *J Manipulative Physiol Ther*. 2011;34(5):306-313. doi:10.1016/j.jmpt.2011.04.006.
6. Jeppesen KM, Bahner DP. Teaching bedside sonography using peer mentoring: a prospective randomized trial. *J Ultrasound Med*. 2012;31(3):455-459.
7. Syperda VA, Trivedi PN, Melo LC, et al. Ultrasonography in preclinical education: a pilot study. *J Am Osteopath Assoc*. 2008;108(10):601-605.
8. Barloon TJ, Brown BP, Abu-Yousef MM, et al. Teaching physical examination of the adult liver with use of real-time sonography. *Acad Radiol*. 1998;5(2):101-103.
9. Cook T, Hunt P, Hoppman R. Emergency medicine leads the way for training medical students in clinician-based ultrasound: a radical paradigm shift in patient imaging. *Acad Emerg Med*. 2007;14(6):558-561.
10. Kobal SL, Trento L, Baharami S, et al. Comparison of effectiveness of hand-carried ultrasound to bedside cardiovascular physical examination. *Am J Cardiol*. 2005;96(7):1002-1006.
11. Moore CL, Copel JA. Point-of-care ultrasonography. *N Engl J Med*. 2011;364(8):749-757. doi:10.1056/NEJMra0909487.
12. Bandinelli F, Melchiorre D, Scazzariello F, Candelieri A, Conforti D, Matucci-Cerinic M. Clinical and radiological evaluation of sacroiliac joints compared with ultrasound examination in early spondyloarthritis. *Rheumatology (Oxford)*. 2013;52(7):1293-1297. doi:10.1093/rheumatology/ket105.
13. Moore AE, Jeffery R, Gray A, Stringer MD. An anatomical ultrasound study of the long posterior sacro-iliac ligament. *Clin Anat*. 2010;23(8):971-977. doi:10.1002/ca.21039.
14. Fryer G. Teaching critical thinking in osteopathy: integrating craft knowledge and evidence-informed approaches. *Int J Osteopath Med*. 2008;11(2):56-61.
15. Kondrashova T, Lockwood MD. Innovative approach to teaching osteopathic manipulative medicine: the integration of ultrasound techniques. *J Am Osteopath Assoc*. 2015;115(4):212-220. doi:10.7556/jaoa.2015.043.
16. Stovall BA, Kumar S. Reliability of bony anatomic landmark asymmetry assessment in the lumbopelvic region: application to osteopathic medical education. *J Am Osteopath Assoc*. 2010;110(11):667-674.
17. Shaw KA, Dougherty JJ, Treffer KD, Glaros AG. Establishing the content validity of palpatory examination for the assessment of the lumbar spine using ultrasonography: a pilot study. *J Am Osteopath Assoc*. 2012;112(12):775-782.
18. Lockwood MD, Kondrashova T, Johnson JC. Relationship between sacral base position, sacral sulcus depth, gender, and body mass index as measured by ultrasonography [abstract P5]. *J Am Osteopath Assoc*. 2013;113(8):e5-e6. doi:10.7556/jaoa.2013.026.
19. Heinking KP, Kappler RE. Pelvis and sacrum. In: Chila AG, executive ed. *Foundations of Osteopathic Medicine*. 3rd ed. Baltimore, MD: Lippincott Williams & Wilkins; 2011:590-596.
20. Halma K, Lockwood MD, Snider E, Vick D. *Outline of Osteopathic Manipulative Procedures: The Kimberly Manual*. Kirksville, MO: A.T. Still University of Health Sciences-Kirksville College of Osteopathic Medicine; 2008:185-228.
21. Nicholas AS, Nicholas EA. *Atlas of Osteopathic Techniques*. 2nd ed. Baltimore, MD: Lippincott Williams & Wilkins; 2012.
22. Mitchell FL, Mitchell PKG. *The Muscle Energy Manual*. Vol 1. East Lansing, MI: MET Press; 1995.
23. Educational Council on Osteopathic Principles. *Glossary of Osteopathic Terminology*. Chevy Chase, MD: American Association of Colleges of Osteopathic Medicine; 2011.

© 2015 American Osteopathic Association