

Mucormycosis in a Patient With AIDS Receiving Systemic Steroids

Andrew Shiau Pan, OMS IV
Latha Srinath, MD

From the Nova Southeastern
University College of
Osteopathic Medicine
in Fort Lauderdale, Florida.

Financial Disclosures:
None reported.

Address correspondence to
Andrew Shiau Pan, OMS IV,
1625 Renaissance
Commons Blvd, Apt 516,
Boynton Beach, FL
33426-8299.

E-mail:
andrew.s.pan@hotmail.com

Submitted
March 24, 2013;
accepted
April 12, 2013.

Mucormycosis is an opportunistic fungal infection with a high mortality rate. Although mucormycosis is relatively rare, recent studies suggest that the incidence is on the rise as a result of increased use of chemotherapy and steroids. The authors present an unusual case of invasive mucormycosis in a hospitalized patient with AIDS who was receiving short-term, high-dose steroids and who had associated steroid-induced diabetes. The patient was otherwise healthy, with no underlying risk factors such as neutropenia or intravenous drug use. The patient developed acute onset of proptosis, vision loss, and invasive *Mucor* in the left maxillary sinus that extended along the optic nerve intracranially. Despite aggressive treatment, the patient died. Physicians should be aware of steroid-induced diabetes as a risk factor for invasive fungal infections such as mucormycosis.

J Am Osteopath Assoc. 2013;113(9):708-711
doi:10.7556/jaoa.2013.037

Mucormycosis is a potentially fatal opportunistic infection caused by the fungi belonging to the order Mucorales. These fungi are ubiquitous in nature, release airborne spores, and cause necrosis by invading blood vessels. Infection is rare; although humans come in contact with Mucorales, an intact innate immune system is sufficient to prevent infection. Rees et al¹ reported an incidence of 1.7 mucormycosis infections for every 1 million individuals from 1992 to 1993 in 3 California counties.

In a review of 929 mucormycosis cases that occurred between 1940 and 2003, Roden et al² reported that the mortality of mucormycosis ranged from 10% to 98%, depending on areas of the body involved.² Diabetes was the most common risk factor (found in 36% of cases), followed by hematologic malignancies (17% of cases) and solid organ or hematopoietic cell transplantation (12% of cases).² Early treatment is important; a study³ of 70 patients with mucormycosis revealed that starting amphotericin B more than 6 days after diagnosis resulted in an almost 2-fold increase in mortality at 12 weeks after diagnosis compared with early treatment (83% vs 49%).

In the current report, we present an unusual case of mucormycosis in a patient with AIDS who was receiving steroids.

Report of Case

Presentation and History

A 39-year-old woman with AIDS and no known history of diabetes mellitus was admitted to the emergency department in late September 2012 for weakness, malaise, and dizziness. In August 2012, the patient had been admitted to the emergency department for seizures and a 1.2-cm enhancing calcified lesion with vasogenic edema in the frontal lobe. At that time, neurocysticercosis with cyst rupture was empirically diagnosed after work-up did not reveal any other cause of symptoms. She was discharged with an ongoing treatment regimen of albendazole (200 mg twice daily), dexamethasone (4 mg twice daily), levetiracetam (750 mg twice daily), and insulin (70% human insulin isophane suspension and 30% human insulin, 40 U twice daily). Medications included highly active antiretroviral therapy (combined zidovudine and lamivudine and combined lopinavir and ritonavir) for AIDS. Her last CD4 cell count (taken earlier that month before presentation) was 139 cells/mm³, with an undetectable viral load. Other notable medical history included deep vein thrombosis and gastroesophageal reflux disease.

Physical Examination

At admission, the patient's vital signs included a temperature of 97.7°F, a pulse of 116 beats/min, a respiration rate of 18 beats/min, and a blood pressure of 98/60 mm Hg. Examination revealed left facial swelling and a protruding left eye that exhibited afferent papillary defect. The patient had vision loss and her left eye was limited in abduction and adduction. The rest of her physical examination was unremarkable.

Laboratory Test Results

At admission, the patient's metabolic panel revealed the following findings (reference ranges appear in parentheses): blood urea nitrogen, 36 mg/dL (5-20 mg/dL); creatinine, 1.00 mg/dL (0.60-1.00 mg/dL); serum glucose, 250 mg/dL (65-100 mg/dL); chloride, 109 mEq/L (98-107

mEq/L); magnesium, 1.6 mEq/L (1.8-2.4 mEq/L); total protein, 6.0 g/dL (6.4-8.2 g/dL); albumin, 1.6 g/dL (3.4-5.0 g/dL); lactate dehydrogenase, 664 U/L (81-234 U/L); alkaline phosphatase, 149 U/L (50-136 U/L); alanine aminotransferase, 83 U/L (12-78 U/L); and aspartate aminotransferase, 54 U/L (10-37 U/L). Hemoglobin A_{1c} was 8.8% (4.5%-6.2%).

Thyroid-stimulating hormone level was 0.133 mIU/L (0.510-6.270 mIU/L), total triiodothyronine uptake was 47.53% (22.5%-37.0%), and total thyroxine was 5.20 ng/dL (4.50-10.90 ng/dL).

White blood cell count was 3.9×10^3 μ L (4.5×10^3 μ L to 11.0×10^3 μ L); hemoglobin, 10.5 g/dL (12.0-16.0 g/dL); hematocrit, 31.3% (37.0%-47.0%); and platelet count, 28×10^3 μ L (150×10^3 μ L to 400×10^3 μ L). Differential blood cell count revealed 87.1% neutrophils and 6.2% lymphocytes. Manual differential count showed 87 segmented neutrophils (33-66) and 2 bands (0-10). Absolute neutrophil count was 3855 cells/ μ L. Total serum iron level was 144 μ g/dL (50-175 μ g/dL), with a ferritin level of 246 ng/mL (10-291 ng/mL).

Findings from the patient's urinalysis and blood cultures were unremarkable.

Imaging

One month after admission (October 2012), a chest radiograph revealed no abnormalities. A magnetic resonance image showed new, expansible fluid collection in the left infraorbital fat and opacification of the left maxillary sinus not present at admission (*Figure 1*). A few opacified left ethmoid air cells were also present. The right frontal, maxillary, and sphenoid sinuses remained clear. No changes were observed in the calcified lesion.

Treatment

The patient was hospitalized and treated for hyperglycemia and thrombocytopenia. She continued to receive steroids and highly active antiretroviral therapy and was evaluated by specialists in the hematology, neurology, ophthalmology, and otolaryngology departments. Bone

marrow biopsy findings revealed no evidence of increased blasts, eosinophilia, monocytosis, or a lymphoproliferative disorder. Subconjunctival biopsy findings showed a minute fragment of conjunctiva containing a capillary hemangioma with mild acute conjunctivitis.

Endoscopic evaluation of the maxillary sinus and middle turbinate revealed necrotic blackened tissue (*Figure 2*). The necrotic tissue of the middle turbinate was removed and sent to the pathology department for evaluation. Fluid was drained out of the maxillary sinus, and the necrotic tissues were débrided. Findings from endoscopic evaluation of the left frontal, sphenoid, and right-sided sinuses were unremarkable.

At microscopic examination, the biopsy specimen showed fungal forms infiltrating into bone. The sinus fluid showed necrotic tissue and a blood clot containing fungal forms that resembled mucormycosis and bone fragments with fungal invasion (*Figure 3*). The patient received amphotericin B (50 mg/d intravenously).

Clinical Course

Despite treatment, the patient's condition deteriorated. In December 2012, a magnetic resonance image showed

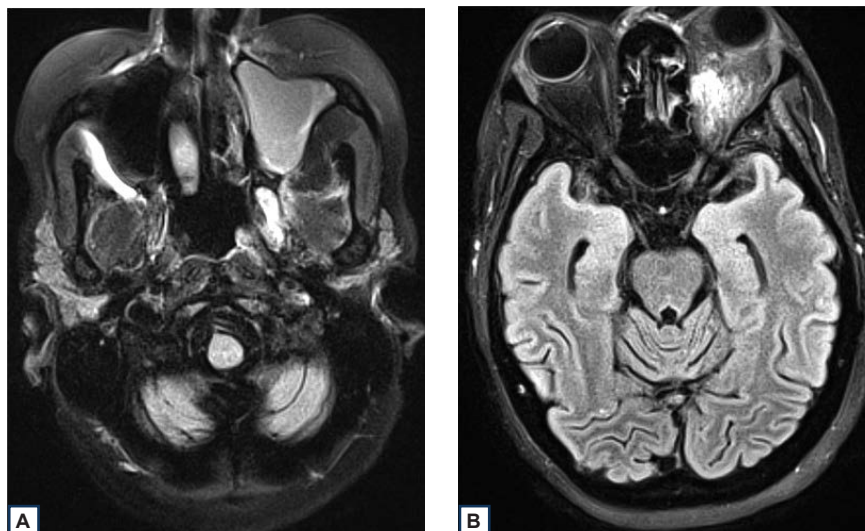
multiple small lesions with vasogenic edema involving the supratentorial areas bilaterally and the cerebellum and brainstem. Air-fluid levels were present in the maxillary sinuses bilaterally. Mucosal thickening was present in the left maxillary sinus, ethmoid air cells, and sphenoid and frontal sinuses. The patient died at the end of December 2012.

Comment

The results of one study⁴ indicated that the incidence of mucormycosis is on the rise in the United States as a result of the increased use of chemotherapy and steroids, which is associated with a prolonged immunocompromised state. According to a study⁵ of 5589 transplant patients at the Fred Hutchinson Cancer Center in Seattle, Washington, the number of mucormycosis cases more than doubled from 1985-1989 to 1995-1999.

Mucormycosis in a patient with human immunodeficiency virus (HIV) is rare, but it can be the presenting opportunistic infection in patients with AIDS.⁶ Predisposing factors for mucormycosis infection in a patient with HIV include low CD4 count, neutropenia, and

Figure 1. Magnetic resonance image showing (A) opacification of the left sphenoid sinus and (B) increased intensity of the left orbit suggesting edema in the infraorbital fat.



active intravenous drug use.⁶ In a review⁷ of 10 reported cases of HIV-positive patients with mucormycosis, 8 patients were intravenous drug users and 1 had drug-induced neutropenia.

Although diabetes mellitus is strongly related to mucormycosis, cases of mucormycosis in patients with steroid-induced diabetes mellitus are rare. In a study of 33 patients with mucormycosis who were treated over a 7-year period, only 1 patient had steroid-induced diabetes mellitus.⁸

Our patient with underlying AIDS who was receiving a high-dose systemic steroid developed invasive mucormycosis. She did not have neutropenia, and she was not an intravenous drug user. In the present case, the combination of immunosuppression and steroid-induced hyperglycemia likely contributed to a relatively higher risk for infection. The patient did not have ketoacidosis related to her hyperglycemia.

Conclusion

Mucormycosis is a deadly infection with a high mortality rate. Physicians should maintain a high degree of suspicion for possible invasive fungal infections, including mucormycosis, in patients with underlying immunodeficiency who are receiving high-dose steroid therapy. Judicious use of steroids and early detection and treatment could improve outcomes in these patients.

References

1. Rees JR, Pinner RW, Hajjeh RA, Brandt ME, Reingold AL. *Clin Infect Dis*. 1998;27(5):1138-1147. <http://cid.oxfordjournals.org/content/27/5/1138.long>. Accessed August 8, 2013.
2. Roden MM, Zaoutis TE, Buchanan WL, et al. Epidemiology and outcome of zygomycosis: a review of 929 reported cases [published online July 29, 2005]. *Clin Infect Dis*. 2005;41(5):634-653.
3. Chamilos G, Lewis RE, Kontoyiannis DP. Delaying amphotericin B-based frontline therapy significantly increases mortality among patients with hematologic malignancy who have zygomycosis. *Clin Infect Dis*. 2008;47(4):503-509.
4. Pagano L, Offidani M, Fianchi L, et al. Mucormycosis in hematologic patients. *Haematologica*. 2004;89(2):207-214.
5. Marr KA, Carter RA, Crippa F, Wald A, Corey L. Epidemiology and outcome of mould infections in hematopoietic stem cell transplant recipients. *Clin Infect Dis*. 2002;34(7):909-917.
6. Moraru RA, Grossman ME. Palatal necrosis in an AIDS patient: a case of mucormycosis. *Cutis*. 2000;66(1):15-18.
7. Sanchez MR, Ponge-Wilson I, Moy JA, Rosenthal S. Zygomycosis and HIV infection. *J Am Acad Dermatol*. 1994;30(5 pt 2):904-908.
8. Goel A, Kini U, Shetty S. Role of histopathology as an aid to prognosis in rhino-orbito-cerebral zygomycosis. *Indian J Pathol Microbiol*. 2010;53(2):253-257.

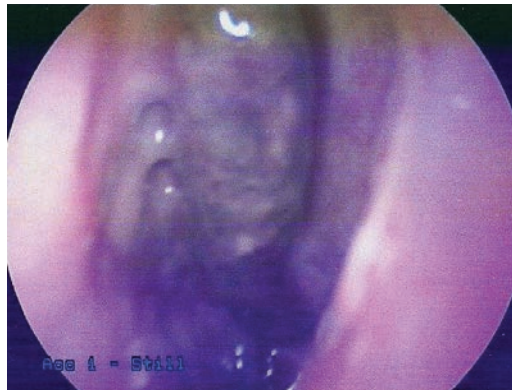

Figure 2. Endoscopic image showing necrosis of the middle turbinate.

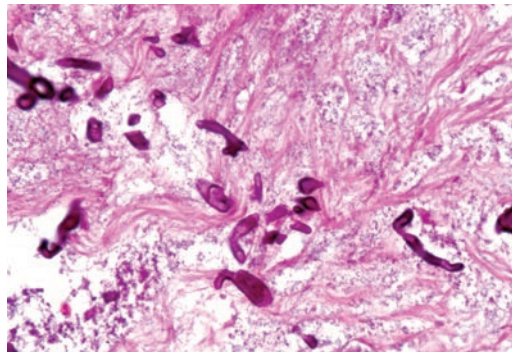


Figure 3. Microscopic image from the left-middle turbinate showing broad, irregular, nonseptate hyphae, which are characteristic of mucormycosis.