

Osteopathic Manipulative Treatment to Resolve Head and Neck Pain After Tooth Extraction

Patricia M. Meyer, DO, MS
Sharon M. Gustowski, DO, MPH

Pain is a common occurrence after tooth extraction and is usually localized to the extraction site. However, clinical experience shows that patients may also have pain in the head or neck in the weeks after this procedure. The authors present a case representative of these findings. In the case, cranial and cervical somatic dysfunction in a patient who had undergone tooth extraction was resolved through the use of osteopathic manipulative treatment. This case emphasizes the need to include a dental history when evaluating head and neck pain as part of comprehensive osteopathic medical care. The case can also serve as a foundation for a detailed discussion regarding how to effectively incorporate osteopathic manipulative treatment into primary care practice for patients who present with head or neck pain after tooth extraction.

J Am Osteopath Assoc. 2012;112(7):457-460

After dental extraction, the majority of patients have pain lasting less than 1 week that can be controlled by analgesics. The length, type, and severity of pain vary as a result of multiple factors, such as the difficulty of the extraction procedure, the patient's health status and attitude, and the patient's sex.¹ Other pain syndromes that may occur weeks after the procedure—though rare—include neuropathic pain, temporomandibular disorder,^{2,3} cluster headache,^{4,5} and neck and head pain caused by somatic dysfunction.^{6,7} Prolonged and nonresolving pain should be investigated for such conditions as rheumatologic diseases, tumors, migraine headache, or myofascial pain syndrome.

The etiologic characteristics of head and neck pain after dental procedures are multifactorial, depending on the type of procedure, the direction and amount of force used, and the patient's predisposing factors (eg, previous injuries). Postextraction head and neck pain is not a well-documented condition, though it is seen in clinical practice. The use of osteopathic structural examination and application of appropriate osteopathic manipulative treatment (OMT) to resolve somatic dysfunction can be offered by osteopathic physicians as treatment modalities beyond pharmacologic and surgical management—or no management at all. The following case is an example of the use of OMT to resolve head and neck pain in a patient after tooth extraction.

Report of Case

A 52-year-old man presented with neck pain, headache, and low back pain that began 2 weeks previously. These symptoms began after a right upper tooth extraction, as well as after he had overstretched his neck and overexerted himself while pushing a car. He believed that these events contributed to his pain. He characterized his neck pain as being like “pins and needles”—a sensation that radiated into his head without causing dizziness. The pain improved somewhat with hot showers and aspirin, and it became worse with movement. He described the pain in his back as stiffness and tightness with motion. He said that he was without weakness, paresthesia, or bowel or bladder incontinence. The patient worked as a salesperson for truck parts.

From the Department of Primary Care, Touro University Nevada College of Osteopathic Medicine in Henderson (Dr Meyer), and the Department of Osteopathic Manipulative Medicine, University of North Texas Health Science Center, Texas College of Osteopathic Medicine in Fort Worth (Dr Gustowski). Dr Meyer's MS degree is in clinical research and education in osteopathic manipulative medicine.

Financial Disclosures: None reported.

Address correspondence to Sharon M. Gustowski, DO, MPH, Assistant Professor, Department of Osteopathic Manipulative Medicine, University of North Texas Health Science Center, Texas College of Osteopathic Medicine, 3500 Camp Bowie Blvd, Fort Worth, TX 76102-4567.

E-mail: sharon.gustowski@unthsc.edu

Submitted August 2, 2011; revision received January 20, 2012; accepted January 27, 2012.

CASE REPORT

The patient's medical history was positive for hypertension, depression, and low back pain, which his primary care physician had previously managed with OMT. The patient had no known drug allergies. His current medications included lisinopril/hydrochlorothiazide, 20 mg/12.5 mg daily; paroxetine, 20 mg daily; and a multivitamin. A review of systems was positive for sore eyes and a feeling of fullness in his left ear.

Physical examination revealed normal vital signs. The patient weighed 172 lb and had a height of 5 ft 8 in. Results of head, eye, ear, nose, and throat; cardiovascular; pulmonary; and neurologic examinations were unremarkable. Musculoskeletal examination yielded positive results for supple and tender cervical paraspinal and lumbar musculature with lower thoracic and lumbar tightness, but with intact range of motion.

The treating physician at the time of this initial patient visit diagnosed cervical strain and lumbar strain and prescribed acetaminophen over the counter as needed; metaxalone, 800 mg, before bedtime; range of motion exercises; and a lifting restriction of no more than 20 lb, with follow-up in 2 weeks if no improvement. An evaluation for somatic dysfunction was not performed, but the patient was referred for OMT or chiropractic treatment.

The patient did not follow up as scheduled, and he did not see an outside specialist. However, he did follow up 2 months after his initial visit with his primary care physician (P.M.M.) because of continued symptoms. At this 2-month follow-up visit, he described neck pain that radiated to the top of his head and behind his eyes, as well as down into the posterior area of his right arm. His head pain was rated as a constant 5 on a pain scale of 10. He denied weakness, numbness, or tingling. The pain would ease with exercise, hot showers, and use of the muscle relaxant.

Physical examination at the 2-month follow-up visit revealed no new findings outside of the musculoskeletal system. Musculoskeletal examination revealed bilateral cervical paravertebral muscle tenderness and ropiness. Cranial somatic dysfunction was present, with decreased cranial rhythmic impulse amplitude and frequency on the right side and with a right restricted occipitomastoid suture. Cervical somatic dysfunction included the occipitoatlantal joint rotated right sidebent left (ie, $R_R S_L$) and cervical vertebrae 3 and 4 rotated right sidebent right (ie, $R_R S_R$). The bilateral first ribs were found to be restricted in inhalation, with a left superior somatic dysfunction. Somatic dysfunction found in thoracic vertebrae 6 through 8 was neutral rotated left sidebent right (ie, $NR_L S_R$). A right bicep tender point was found. No tricep tender point was found.

Osteopathic manipulative treatment was performed at the 2-month follow-up visit. The cranial dysfunction was addressed using parietal and frontal lifts, as well as the v-spread technique.⁸ Muscle energy, myofascial release,

counterstrain, and articulatory techniques⁹ were applied to the cervical spine. The thoracic spine dysfunction was treated using the high-velocity, low-amplitude technique,⁹ and the rib dysfunction was resolved using the Still technique.¹⁰

The patient reported substantial improvement in his symptoms on a follow-up visit 1 week after receiving OMT. He had resolution of his headaches, minimal residual pain in his neck, and a decrease in his arm tenderness. The patient was again treated with OMT at this visit, with complete resolution of his symptoms.

Comment

Tooth extraction is a traumatic event, albeit a necessary procedure, used to treat patients with severe dental caries or malocclusion. The physical forces required to perform a tooth extraction often exceed forces the body can accommodate without an adverse response. Rather than causing fracture or tears, the strain that is introduced into the cranial musculature and sutures can lead to misalignment of the cranial bone articulations¹¹—a misalignment called cranial somatic dysfunction. Somatic dysfunction is, by definition, a condition in which there is “[i]mpaired or altered function of related components of the somatic (body framework) system: skeletal, arthrodiastal and myofascial structures, and related vascular, lymphatic, and neural elements.”¹²

The cranium has unique palpable anatomic and physiologic characteristics that become altered when somatic dysfunction occurs. Normally, the brain and spinal cord, cerebrospinal fluid, cranial and spinal dural membranes, cranial bones, and sacrum have coordinated functions and a movement pattern called the primary respiratory mechanism.¹² The motion that can be palpated is called the cranial rhythmic impulse.¹² Each component of the primary respiratory mechanism must be present and without somatic dysfunction for optimum function, which includes unobstructed circulation of fluids and absence of dural and nociceptive afferent input. Palpation of the cranium for somatic dysfunction is taught at most colleges of osteopathic medicine and is used in practice by many osteopathic physicians.

William Garner Sutherland, DO, proposed a mechanism for the induction of cranial strain through dental extractions.¹³ He theorized that the side-to-side leverage used to extract the tooth with forceps, combined with posterior occiput compression caused by the V-shaped headrest commonly used at the time, results in somatic dysfunction of the mandible, maxilla, sphenoid, and temporal bones. Although the V-shaped headrest is not commonly used in modern dentistry, the action used to extract a tooth has largely remained unchanged. The side-to-side leverage disrupts the alignment of the cranial bones and can lead to abnormal function of the muscles of mastication and strain in the dura mater. Both of these structures—the mus-

cles and the dura—transmit painful stimuli when abnormal stressors, such as excessive stretch, are placed on them.

The particular cranial dysfunctions that are induced will vary depending on whether an upper or a lower molar was extracted. These dysfunctions can be anticipated by knowing how the cranial sutures are beveled. The following text describes the cranial strains that commonly occur. The description should not be viewed as the only cranial dysfunctions that may be present after dental extractions.

In an upper molar extraction, the maxilla is pulled inferiorly and laterally and, therefore, impinges upon the coronoid process of the mandible. These motions disrupt the normal alignment of the temporomandibular joint,¹³ an arthroal joint in which the mandible articulates with the temporal bone. The temporal bone then becomes compressed into the occiput at the occipitomastoid suture. Temporomandibular joint movements include depression or elevation of the jaw by opening or closing the mouth, as well as a protrusion and retrusion motion of the jaw.⁸ Misalignment of the temporomandibular joint leads to restriction of motion, malocclusion, alteration of the tension of the mastication muscles, and subsequent head and neck pain.¹⁴ The patient in the present case followed this pattern, with temporal bone somatic dysfunction and occipitomastoid suture compression (*Figure*).

Lower molar extractions tend to compress the temporal bone at the mandibular articulation on the same side of

the extraction. In a lower molar extraction, the side-to-side leverage pulls the opposite mandibular articulation inferiorly. Increased strain is induced in the sphenomandibular ligament, and the sphenoid bone is pulled inferiorly and laterally on the side opposite the extraction.

The sphenoid bone forms an anatomically significant part of the orbit, houses the cavernous sinus, and has foramina through which the orbital nerves, arteries, and veins pass. Alteration of the size or shape of the foramina can directly affect the structures that pass through them. The trigeminal nerve's 3 branches enter through the sphenoid—the ophthalmic nerve (V_1) via the supraorbital fissure, the maxillary nerve (V_2) via the foramen rotundum, and the mandibular nerve (V_3) via the foramen ovale.⁶ Magoun⁶ describes trigeminal neuralgia in predisposed patients after upper and lower dental extractions as a result of dysfunction of the temporal, sphenoid, maxilla, and mandible bones. He documents improvement in patient symptoms with the application of various cranial techniques to these areas.⁶ Sphenoid strain through its effect on the orbit can also lead to dysfunctional movement of the extraocular muscles, many of which attach to the common annular tendon that is on the main body and lesser wings of the sphenoid bone.¹³

Libin¹⁵ proposed that the interjaw space between the maxilla and mandible bones be considered to function like a cranial suture. It is the goal of osteopathic medicine that this suture, like all other cranial sutures, have friction-free physiologic motion.¹⁵ The physiologic motion of the cranium can be disrupted by dental malocclusion, incorrectly positioned teeth, and dental trauma. The motions of the mandible and maxilla are important to address—not only when the mouth is open, but also with closure of the mouth. If malocclusion is present, the cranial mechanism will be affected through articulation of the mandible with the temporal bones and, thereby, the sphenobasilar junction. Dental prostheses must be fitted and adjusted so as not to restrict motion—especially when extending across the midline of the face. Tight dentures, retainers, or night guards can be a cause of cranial dysfunction.¹

Although muscle dysfunction was not specifically addressed in the present case, the patient's pain was consistent with patterns of levator scapulae and trapezius trigger point pain. The patient described pain coming from

the base of the skull and neck and radiating to the orbit and vertex and down to the right arm. A trigger point is defined as "a focus of hyperirritability in a tissue that, when compressed, is locally tender and ... gives rise to referred pain and tenderness."¹⁶ A trigger point in the

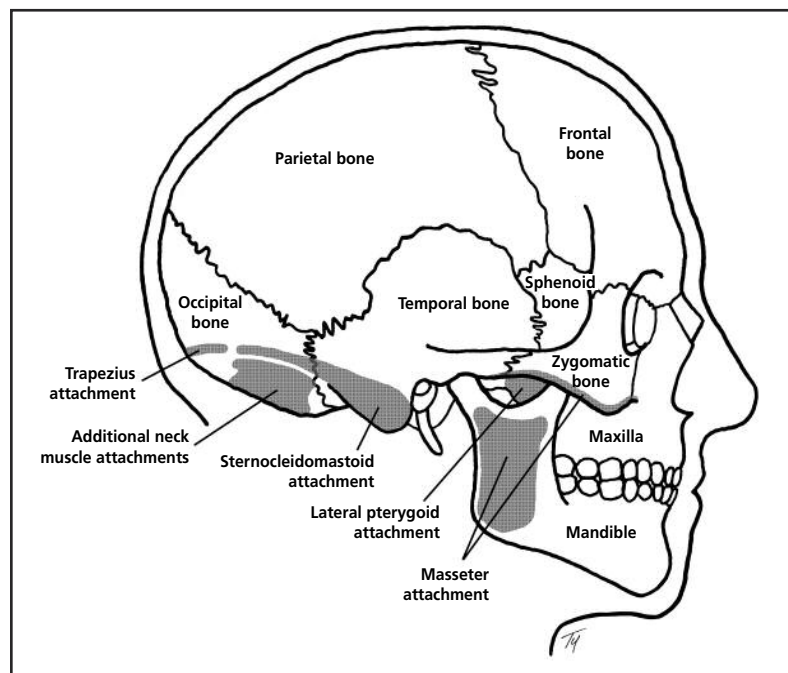


Figure. Cranial bones with muscular attachments (shown in gray) relevant to upper molar extraction, which disrupts the normal alignment of the temporomandibular joint. Misalignment of this joint leads to restriction of motion, malocclusion, alteration of the tension of the mastication muscles, and subsequent head and neck pain.

CASE REPORT

upper trapezius fibers refers pain around the side of the head into the orbit. Lower trapezius trigger points refer into the suprascapular area.¹⁶ A trigger point in the levator scapulae radiates down the shoulder into the posterior arm¹⁶—consistent with the patient's description of pain without tender points within the posterior arm. The muscular component of these symptoms could have arisen from increased muscle tension related to anxiety and pain during the tooth extraction, as well as the continued cranial dysfunction that went untreated for months. Evaluation of muscular somatic dysfunction or trigger points may assist in the management of this type of condition.

In the course of a 15-minute office visit, the movements of all aspects of the face and cranium cannot be palpated and evaluated. A focus on key areas of restriction, including the occipitomastoid suture, the occipitoatlantal joint, and the temporal bones, can provide the basis of a treatment plan. Addressing these key areas with OMT can lead to clinically significant improvement in patients' cranial motion and symptoms.

Conclusion

Head and neck pain are common complaints addressed by primary care physicians. The present case emphasizes the need to include a thorough musculoskeletal trauma history and physical examination when evaluating patients. Cervical and cranial somatic dysfunction may be caused by dental trauma. A history of dental trauma should clue the osteopathic physician into examination of the cranium and cervical spine for somatic dysfunction. Although some osteopathic physicians consider cranial palpation to be an advanced skill, this should not preclude all osteopathic physicians from having an index of suspicion for tissue texture changes or from palpating the suboccipital musculature for such changes. If the patient's suboccipital musculature has tissue texture changes and if the patient has a history of dental trauma, an appropriate management strategy would be to perform OMT—or to refer the patient to a specialist in neuromusculoskeletal medicine/osteopathic manipulative medicine if the primary care physician is unable to perform OMT.

Acknowledgments

We acknowledge and thank Todd Yokley, PhD, from the Department of Basic Sciences at Touro University Nevada College of Osteopathic Medicine for creating the illustration used in this article.

References

1. Al-Khateeb TH, Alnabar A. Pain experience after simple tooth extraction. *J Oral Maxillofac Surg*. 2008;66(5):911-917.
2. Juhl GI, Jensen TS, Norholt SE, Svensson P. Incidence of symptoms and signs of TMD following third molar surgery: a controlled, prospective study. *J Oral Rehabil*. 2009;36(3):199-209.
3. Meyer R. Temporomandibular joint pain. In: Walker HK, Hall WD, Hurst JW. *Clinical Methods: The History, Physical, and Laboratory Examinations*. 3rd ed. Boston, MA: Butterworth-Heinemann; 1990:761-762.
4. Peñarrocha M, Bandrés A, Peñarrocha MA, Bagán JV. Relationship between oral surgical and endodontic procedures and episodic cluster headache. *Oral Surg Oral Med Oral Pathol Oral Radiol Endod*. 2001;92(5):499-502.
5. Sörös P, Frese A, Husstedt IW, Evers S. Cluster headache after dental extraction: implications for the pathogenesis of cluster headache? *Cephalalgia*. 2001;21(5):619-622.
6. Magoun HI. *Osteopathy in the Cranial Field*. 3rd ed. Indianapolis, IN: The Cranial Academy; 1976:295-300.
7. Heinking K, Kappler R, Ramey K. Head and occipital region. In: Chila AG, executive ed. *Foundations of Osteopathic Medicine*. 3rd ed. Baltimore, MD: Lippincott Williams & Wilkins; 2010:491,507.
8. Sutherland S, ed. *Expanding the Osteopathic Concept: A Manual for the Colleges of Osteopathic Medicine*. Pomona, CA: College of Osteopathic Medicine of the Pacific; 1993:III/5-11,IV/22-23.
9. Kimberly P, Funk SF, eds. *Outline of Osteopathic Manipulative Procedures: the Kimberly Manual, Millennium Edition*. Marceline, MO: Walsworth Publishing Company; 2000:68,70,73,80.
10. Buskirk R. Still technique. In: Chila AG, executive ed. *Foundations of Osteopathic Medicine*. 3rd ed. Baltimore, MD: Lippincott Williams & Wilkins; 2011:851.
11. Gillespie BR. Dental considerations of the craniosacral mechanism. *Cranio*. 1985;3(4):380-384.
12. Educational Council on Osteopathic Principles. *Glossary of Osteopathic Terminology*. Rev ed. Chevy Chase, MD: American Association of Colleges of Osteopathic Medicine; April 2009.
13. Sutherland WG. Dental traumatic cranial lesions. *Osteopath Profession*. April 1937;4(7):9,50,52,54.
14. Scriveri SJ, Keith DA, Kaban LB. Temporomandibular disorders. *N Engl J Med*. 2008;359(25):2693-2705.
15. Libin BM. Cranial osteopathy and dental occlusion. *Cranial Academy Newsletter*. Summer 1996;39(3):3.
16. Travell JG, Simons DG. *Myofascial Pain and Dysfunction: The Trigger Point Manual, The Upper Extremities*. Vol 1. Baltimore, MD: Williams and Wilkins; 1983:4,183-190,334-337.