

## Mountaineering-Induced Bilateral Plantar Paresthesia

Kyle K. Henderson, PhD

Justine Parker, DO

Kurt P. Heinking, DO

From the departments of physiology (Dr Henderson) and osteopathic manipulative medicine (Dr Heinking) at the Midwestern University/Chicago College of Osteopathic Medicine in Downers Grove, Illinois, and from Advocate Illinois Masonic Medical Center in Downers Grove, Illinois (Dr Parker). At the time of submission, Dr Parker was an osteopathic medical student at the Midwestern University/Chicago College of Osteopathic Medicine.

Financial Disclosures:  
None reported.

Support: None reported.

Address correspondence to Kyle K. Henderson, PhD, Midwestern University/Chicago College of Osteopathic Medicine, Department of Physiology, 555 31st St, Downers Grove, IL 60515-1235.

E-mail:  
khende@midwestern.edu

Submitted May 17, 2013;  
final revision received  
October 18, 2013; accepted  
November 6, 2013.

**Context:** Flat feet (pes planus) have been implicated in multiple musculoskeletal complaints, which are often exacerbated by lack of appropriate arch support or intense exercise.

**Objective:** To investigate the efficacy of osteopathic manipulative treatment (OMT) on a patient (K.K.H.) with mountaineering-induced bilateral plantar paresthesia and to assess the association of pes planus with paresthesia in members of the mountaineering expedition party that accompanied the patient.

**Methods:** A patient history and physical examination of the musculoskeletal system were performed. The hindfoot, midfoot, forefoot, big toe, and distal toes were evaluated for neurologic function, specifically pin, vibration, 10-g weight sensitivity, and 2-point discrimination during the 4-month treatment period. To determine if OMT could augment recovery, the patient volunteered to use the contralateral leg as a control, with no OMT performed on the sacrum or lower back. To determine if pes planus was associated with mountaineering-induced paresthesia, a sit-to-stand navicular drop test was performed on members of the expedition party.

**Results:** Osteopathic manipulative treatment improved fibular head motion and muscular flexibility and released fascial restrictions of the soleus, hamstring, popliteus, and gastrocnemius. The patient's perception of stiffness, pain, and overall well-being improved with OMT. However, OMT did not shorten the duration of paresthesia. Of the 9 expedition members, 2 experienced paresthesia. Average navicular drop on standing was 5.1 mm for participants with no paresthesia vs 8.9 mm for participants with paresthesia (*t* test,  $P < .01$ ; Mann-Whitney rank sum test,  $P = .06$ ).

**Conclusion:** These preliminary findings suggest that weakened arches may contribute to mountaineering-induced plantar paresthesia. Early diagnosis of pes planus and treatment with orthotics (which may prevent neuropathies)—or, less ideally, OMT after extreme exercise—should be sought to relieve tension and discomfort.

*J Am Osteopath Assoc.* 2014;114(7):549-555  
doi:10.7556/jaoa.2014.108

Lower extremity peripheral nerve injury is a rare but serious complication of intense exercise, one that can result in pain, paresthesia, and even permanent neurologic damage.<sup>1-4</sup> Athletes who wear inflexible and form-fitting boots are prone to local compression and stretching of the distal lower extremity nerves.<sup>5,6</sup> Specifically, the anterior superficial and deep peroneal nerves, and the posterior tibial nerve may be at risk. With any distal neuropathy, a comprehensive knowledge of anatomy is important for diagnosis and treatment.

The tibial nerve passes under the flexor retinaculum at the ankle as the nerve extends posteriorly and distally.<sup>7</sup> It provides sensation to the plantar aspect of the foot and toes. Tarsal tunnel syndrome is a compression neuropathy that causes paresthesias in the tibial nerve distribution. Compression can be intrinsic from a cyst or osteophyte, extrinsic from repetitive trauma caused by shoe pressure, or from a combination of these factors.<sup>4,8</sup> Tenosynovitis of the 4 nearby tendons can put pressure on the nerve in the nonaccommodating tarsal tunnel and cause paresthesias. Alternatively, pronation of the foot may increase tarsal tunnel pressure as well as tension (stretch) on the tibial nerve (*Figure 1*) and contribute to paresthesias.<sup>9-11</sup> In support of this theory, pronation has been shown to decrease tarsal tunnel compartment volume in healthy participants.<sup>12</sup> The decrease in compartment volume would theoretically increase tarsal tunnel pressure, which has been demonstrated in studies using the feet of cadavers.<sup>11</sup> Additional in vitro studies have also demonstrated that pronation increases tibial nerve tension.<sup>13</sup> Because the symptoms of compression and tension neuropathies are similar, the exact mechanism cannot be identified by clinical examination alone.

The superficial peroneal nerve (*Figure 1*) travels in the lateral compartment and divides into the medial and intermediate dorsal cutaneous nerves at approximately 4 to 6 cm proximal to the ankle joint anteriorly.<sup>14</sup> It supplies sensation to the dorsum of the foot except for the web between the big toe and the second toe. The deep peroneal nerve courses lateral to the anterior tibial muscle before passing under the extensor retinaculum to enter the foot.<sup>15</sup> The nerve's cutaneous branches supply sensation to the web between the first and second toes. Local repetitive mechanical irritation or compression is the most common underlying cause of entrapment of these nerves (*Figure 1*). Entrapment of the deep peroneal nerve beneath the superior edge of the retinaculum may result from inflammation of 1 of the 4 tendons that also travel in the tunnel. This entrapment is referred to as *anterior tarsal tunnel syndrome*.<sup>16</sup> Compression of the



**Figure 1.**

Patient's mountaineering boot with crampon. Boots were rarely fully laced to maintain ankle flexibility during glacial travel. Pronation of the arch may contribute to stretch-induced injury of the tibial nerve (A), and compression along the anterior compartment could lead to entrapment of the peroneal nerves (B).

nerves can also occur distally at the level of the talonavicular joint or at the level of the first and second tarsometatarsal joints, most commonly from tight shoes.<sup>2,7,8,16</sup>

In the current brief report, we assessed the efficacy of osteopathic manipulative treatment (OMT) in a patient (K.K.H., who initiated the study and is an investigator-author) with mountaineering-induced bilateral plantar paresthesia, as well as investigated whether pes planus is associated with mountaineering-induced plantar paresthesia.

## Methods

A medical history was taken and a complete physical examination of the musculoskeletal system performed on a patient (K.K.H.) who presented with mountaineering-induced bilateral plantar paresthesia. Neurologic function of the foot was measured during the 4-month treatment period. Osteopathic manipulative treatment

was performed (K.P.H.) on the right lower extremity using direct and indirect techniques biweekly for the first month and then weekly for months 2, 3, and 4 of the study.

In addition, institutional review board approval was obtained to perform a modified sit-to-stand navicular drop test<sup>17-19</sup> on members of the expedition party, all of whom provided informed consent to participate in the study. The right and left navicular tuberosity were identified and marked with a fine-tipped pen. Each participant sat on a chair with a height that resulted in an approximately 90° bend at the knee, with shins perpendicular to the ground. The width for the stance was adjusted to the length of each participant's forearm. A notecard was positioned at a perpendicular angle to the ground and the height of the navicular tuberosity was marked. Each participant was then asked to stand up with equal weight distribution, and the height of the navicular tuberosity was remarked. The hindfoot, midfoot, forefoot, big toe, and distal toes were evaluated for neurologic function,<sup>20</sup> specifically pin, vibration, 10-g weight sensitivity, and 2-point discrimination.

We used *t* tests for statistical comparisons using SigmaPlot 12.3.0 (Systat Software Inc), where  $P < .05$  was considered statistically significant. Because of the small sample size, a more conservative Mann-Whitney rank sum test was also used with concordant numbers to provide greater confidence in statistical interpretation.

## Results

### Patient

#### *Presentation and Medical History*

A 43-year-old man (K.K.H.) presented to an academic outpatient clinic in 2012 with bilateral paresthesia, which began after a 7-day mountaineering expedition that required extensive glacial travel in mountaineering boots with crampons (*Figure 1*). The patient was carrying a pack weighing approximately 25 kg and wearing boots with inflexible soles (3.1 kg) and no orthotics.

The patient reported mild and constant numbness of the feet from the toes to the midfoot, which began insidiously after the latest trip. Numbness was worse in the morning, with no pain. The patient reported a similar episode in August 2011, also after a 7-day mountaineering trip, in which the numbness slowly dissipated with complete resolution in approximately 4 months. The patient had full sensation of his feet before the 2012 expedition.

Medical history was notable for a motor vehicle accident in 1989 resulting in multiple fractures; right acromioclavicular joint separation in 1991 requiring surgical intervention; kidney stones; and a meniscal tear in 2011 requiring surgical intervention. Neither the patient nor his family had a history of diabetes mellitus, peripheral vascular disease, lumbosacral nerve root impingement, or other muscular, neurologic, or vascular problems. The patient denied drug use and described his diet as well-rounded with an occasional multivitamin. His most recent laboratory results revealed normal levels of fasting serum glucose, calcium, albumin, total protein, and electrolytes (sodium, potassium, chloride, and total carbon dioxide). No abnormalities were found in test results for kidney (blood urea nitrogen and creatinine), liver (alkaline phosphatase, alanine aminotransferase, aspartate aminotransferase, and total bilirubin), or thyroid function (thyroid-stimulating hormone).

#### *Physical Examination*

Physical examination revealed a physically fit man with a pleasant affect and stable vital signs (blood pressure, 120/70 mm Hg; temperature, 98.2°F; heart rate, 56 beats per minute; respiratory rate, 12 breaths per minute; body mass index, 25.1). Results from heart, lung, and abdominal examinations were unremarkable. Inspection of the feet for palpable space-occupying lesions did not reveal any masses; there were subungual hematomas bilaterally on the second toes.

Examination of the musculoskeletal system revealed bilaterally equal pulses, 2/4 deep tendon reflexes, and 5/5 lower extremity muscle strength. Skin temperature and

capillary refill time were normal. Results from a Tinel test (performed posterior to the medial malleolus), a straight leg test, and a squeeze test for Morton neuroma were all negative bilaterally. Osteopathic musculoskeletal examination revealed articular, muscular, and fascial dysfunction of the lower extremities (posterior fibular head; fascial restriction over the anterior tibial muscle and knee; dropped navicular and first cuboid; hypertonicity of popliteus and proximal gastrocnemius and soleus muscles; anterior lateral malleolus; and tender points in the hamstring, popliteal, and medial gastrocnemius muscles). The patient received a diagnosis of bilateral plantar paresthesia and possible tarsal tunnel syndrome. Because the paresthesia from the previous year had resolved spontaneously, the patient volunteered to use the left leg as a control to determine whether OMT could augment recovery. Accordingly, somatic dysfunction was managed with direct and indirect techniques on the right lower extremity only, whereas the lower back and left leg were untreated.

#### Neurologic Function

Each region that we assessed for neurologic function—hindfoot, midfoot, forefoot, big toe, and distal toes—was responsive, with no apparent sensory loss. A 2-point discrimination test was also used to assess the patient and revealed no sensory loss or sensory gain over the 4-month treatment period.

#### Efficacy of OMT

During the course of treatment, the treating physician (K.P.H.) documented differences in severity of somatic dysfunction between the right and left legs. Improvements in the right leg were noted only in fibular head motion, muscular flexibility (range of motion), and release of fascial restrictions of the soleus, hamstring, popliteal, and gastrocnemius muscles. The patient reported no difference in the severity or area of paresthesias between feet during the treatment but noted reductions in muscular stiffness and improved range of

motion in the right leg. Paresthesia in both feet resolved in late December (ie, 5 months later), and the patient was directed to use orthotics and return to the clinic for OMT before his next mountaineering trip.<sup>17-19</sup>

#### Expedition Party and Navicular Drop Test

Characteristics of the expedition party (N=9) are presented in the *Table*. There were no statistically significant differences in age, weight, height, body mass index, or right or left navicular height in the seated position in the participants who developed paresthesia vs those who did not. However, on standing, the right and left navicular drop of the participants with paresthesia was greater than that of participants with no paresthesia (*t* test,  $P < .01$ ; Mann-Whitney rank sum test,  $P = .06$ ). Because there were only 2 participants with paresthesia, standard error could not be calculated. Therefore, individual data are plotted in *Figure 2* against the group mean (standard error of the mean) for the participants without paresthesia.

#### Discussion

As was seen in the present patient, paresthesia of nerves anterior and posterior to the ankle mortise can be caused by repetitive microtrauma during exercise intensified by pes planus and constrictive shoe wear. Specifically, pronation of the feet may stretch the posterior tibial nerve and secondarily increase compression of the peroneal nerves (*Figure 1*), thereby contributing to paresthesia. Additional factors may include swelling or tenosynovitis of the flexor hallucis longus, flexor digitorum longus, and posterior tibial muscles. Swelling of these tendon sheaths could decrease space within the tarsal tunnel, compressing the posterior tibial nerve. This form of nerve compression may lead to muscle inhibition (from tenosynovitis) and further contribute to foot overpronation.

Conservative care for distal lower extremity neuropathies involves patient education, which may eliminate predisposing factors. For example, adding padding to the tongue of the shoe, loosening laces, or using alternative

**Table.**  
**Characteristics of a Mountaineering Expedition Party by Participant and Presence of Paresthesia (N=9)**

Characteristic	Age	Weight, kg	Height, cm	BMI	Navicular Height, mm		Navicular Drop, mm	
					Right	Left	Right	Left
<b>Participant</b>								
1	31	104.5	185.4	30.3	57	60	5	6.5
2 <sup>a</sup>	27	63.6	172.7	21.3	42.5	48	5	4.5
3	59	89.1	185.4	25.9	54	50	6	3.5
4	26	84.1	188.0	23.8	52	46	7.5	7
5	55	90.0	190.5	24.7	55.5	61.5	4	5.5
6 <sup>a</sup>	25	59.1	172.7	19.8	48.5	50.5	6	3.5
7	25	73.6	177.8	23.2	55.5	54.5	2.5	5
8	30	100.0	182.9	29.8	54	57	9	10.5
9	43	77.3	175.3	25.1	47	48	8	8
<b>Mean Data</b>								
All	35.7	82.4	181.2	24.9	51.8	52.8	5.9	6.0
No paresthesia <sup>b</sup>	35.4	80.6	181.8	24.1	52.1	52.9	5.1	5.1
Paresthesia <sup>c</sup>	36.5	88.6	179.1	27.5	50.5	52.5	8.5	9.3
<b>P Value</b>								
t test	.928	.551	.646	.263	.699	.932	.027	.008
Mann-Whitney rank sum test	.667	.667	.667	.333	.500	.889	.056	.056

<sup>a</sup> Female participant. All other participants were men.

<sup>b</sup> n=7.

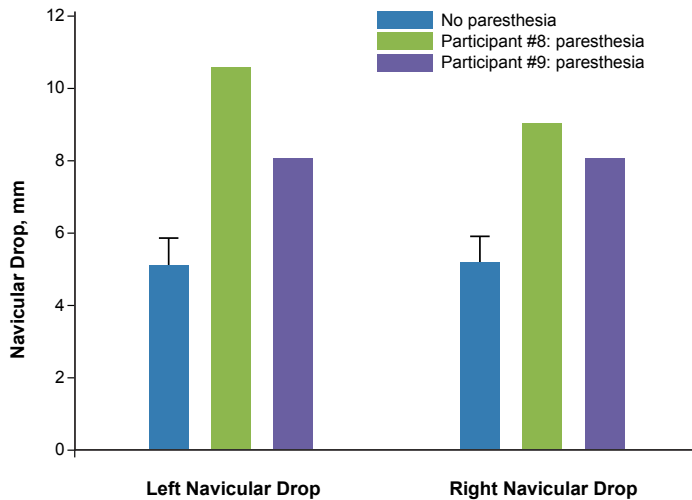
<sup>c</sup> n=2.

**Abbreviation:** BMI, body mass index.

lacing methods may be sufficient to resolve symptoms. Orthotic devices are useful for correction of a biomechanical malalignment in patients with severe valgus or overpronated feet and have been suggested as a treatment for patients with both peroneal and posterior tibial neuropathies.<sup>8,16</sup>

Similar to the findings in the present case, numb toes (digitalgia paresthetica) have been identified in military recruits marching with heavy packs,<sup>24</sup> skiers,<sup>6</sup> and long-distance backpackers.<sup>5</sup> The combination of pes planus,

repetitive microtrauma, and prolonged compression may have contributed to neural lesioning, ischemia, inflammation, and edema, thereby leading to the temporary loss of sensory function. Based on Seddon's classification of nerve injury,<sup>25</sup> the sensory loss could be characterized as a neurapraxia (acute sensory or motor loss). However, the 5-month time to recovery does not exclude axonotmesis (sensory or motor loss secondary to axon or myelin sheath damage), which would require longer recovery secondary to peripheral nerve regeneration.



**Figure 2.**

Sit-to-stand navicular drop (in millimeters) in left and right feet for participants with no paresthesia (mean [standard error of the mean]) and participants who developed paresthesia (no. 8 and no. 9).

The physical examination findings in the present patient are an important reminder of the variety of presentations distal nerve injuries can have. Although the patient presented with mild numbness, severe cases may include the loss of strength, clawing of toes, burning, and pain. The patient's findings were consistent with a partial lesion, one that involved sensory nerves only<sup>8</sup> and that resolved gradually over time, regardless of OMT.<sup>5</sup> Tinel sign is often present, though not always as was the case in our patient.<sup>9</sup> Key considerations in the approach to a patient with plantar paresthesia include awareness, appropriate history, and physical examination including provocative tension signs of the lumbar spine to rule out lumbar nerve root pathology.

To ensure comparisons were made in participants with similar workloads (severity and duration of repetitive foot trauma), our sample size was limited to the 9 members of the patient's expedition party. Whereas *t* tests demonstrated a statistically significant sit-to-

stand navicular drop, we are cautious regarding data interpretation. The data from *Figure 2* suggest that navicular drop on standing was greater in the climbers who developed paresthesia and support the hypothesis that foot overpronation may contribute to mountaineering-induced plantar paresthesia. Validation of this hypothesis will require a greater sample size and should incorporate additional measures for foot overpronation.<sup>21-23</sup> Proof of concept will require the use of orthotics in participants who developed paresthesia in a similarly controlled expedition.<sup>24-26</sup>

The present pilot study had some limitations. First, we could not fully evaluate the effect of OMT on plantar paresthesia because OMT applied to the lumbar spine would have impacted the autonomic, circulatory, and lymphatic tone of both legs. In other words, to ensure the contralateral leg's status as a control, lumbar spine and pelvis dysfunction were left untreated, which may have limited the efficacy of OMT on plantar paresthesia. Second, the main clinical and patient measures of OMT were subjective. In the future, palpatory changes in tissue texture, asymmetry, restriction of motion, and tenderness (ie, the TART criteria) should be quantitatively measured through the use of the Somatic Dysfunction Severity Scale.<sup>26</sup> Third, because the patient (K.K.H.) was also an investigator, a potential conflict of interest may exist.

## Conclusion

The ideal intervention for lower extremity neuropathies resulting from rigorous physical activity is prophylaxis involving appropriate equipment, conditioning, and technique. From an osteopathic perspective, this intervention entails using appropriately fitting boots, arch supports that reduce the stress of hiking on distal nerves, and OMT to manage somatic dysfunction. This approach may reduce the need for typical treatment (eg, removing athletes from their sport, prescribing anti-inflammatory drugs that have gastrointestinal risk, immobilizing the affected muscles, undergoing surgery). Our data suggest

pes planus (as diagnosed by the sit-to-stand navicular drop test) may contribute to digitalgia paresthetica induced by mountaineering. By diagnosing pes planus and correcting dysfunction with orthotics, osteopathic physicians may play an effective role in preventing plantar paresthesia in athletes with constrictive footwear.

### Author Contributions

Drs Henderson, Parker, and Heinking provided substantial contribution to conception and design, acquisition of data, or analysis and interpretation of data; Drs Henderson and Parker drafted the article or revised it critically for important intellectual content; and Drs Henderson, Parker, and Heinking gave final approval of the version of the article to be published.

### References

- Hirasawa Y, Sakakida K. Sports and peripheral nerve injury. *Am J Sports Med.* 1983;11(6):420-426.
- Lorei MP, Hershman EB. Peripheral nerve injuries in athletes: treatment and prevention. *Sports Med.* 1993;16(2):130-147.
- Toth C. Peripheral nerve injuries attributable to sport and recreation. *Neural Clin.* 2008;26(1):89-113;viii-ix. doi:10.1016/j.ncl.2007.11.002.
- Feinberg JH, Nadler SF, Krivickas LS. Peripheral nerve injuries in the athlete. *Sports Med.* 1997;24(6):385-408.
- Boulware DR. Backpacking-induced paresthesias. *Wilderness Environ Med.* 2003;14(3):161-166.
- Lindenbaum BL. Ski boot compression syndrome. *Clin Orthop Relat Res.* 1979;(140):109-110.
- Beltran LS, Bencardino J, Ghazikhanian V, Beltran J. Entrapment neuropathies III: lower limb [published online November 11, 2010]. *Semin Musculoskelet Radiol.* 2010;14(5):501-511. doi:10.1055/s-0030-1268070.
- Hirose CB, McGarvey WC. Peripheral nerve entrapments. *Foot Ankle Clin.* 2004;9(2):255-269.
- Franson J, Baravarian B. Tarsal tunnel syndrome: a compression neuropathy involving four distinct tunnels. *Clin Podiatr Med Surg.* 2006;23(3):597-609.
- Mann RA. Increased pressures in the tarsal tunnel with various foot positions. *Foot Ankle Int.* 2000;21(7):616-617.
- Trepman E, Kadel NJ, Chisholm K, Razzano L. Effect of foot and ankle position on tarsal tunnel compartment pressure. *Foot Ankle Int.* 1999;20(11):721-726.
- Bracilovic A, Nihal A, Houston VL, Beattie AC, Rosenberg ZS, Trepman E. Effect of foot and ankle position on tarsal tunnel compartment volume. *Foot Ankle Int.* 2006;27(6):431-437.
- Daniels TR, Lau JT, Hearn TC. The effects of foot position and load on tibial nerve tension. *Foot Ankle Int.* 1998;19(2):73-78.
- Ducic I, Dellon AL, Graw KS. The clinical importance of variations in the surgical anatomy of the superficial peroneal nerve in the mid-third of the lateral leg. *Ann Plast Surg.* 2006;56(6):635-638.
- Aktan Ikiz ZA, Ucerler H, Uygur M. Dimensions of the anterior tarsal tunnel and features of the deep peroneal nerve in relation to clinical application. *Surg Radiol Anat.* 2007;29(7):527-530.
- DiDomenico LA, Masternick EB. Anterior tarsal tunnel syndrome. *Clin Podiatr Med Surg.* 2006;23(3):611-620.
- Periyasamy R, Manivannan M, Narayanamurthy VB. Correlation between two-point discrimination with other measures of sensory loss in diabetes mellitus patients. *Int J Diabetes Dev Ctries.* 2008;28(3):71-78. doi:10.4103/0973-3930.44076.
- Cowan DN, Jones BH, Robinson JR. Foot morphologic characteristics and risk of exercise-related injury. *Arch Fam Med.* 1993;2(7):773-777.
- Hoppenfeld S, Hutton R. *Physical Examination of the Spine and Extremities.* New York, NY: Appleton-Century-Crofts; 1976.
- McPoil TG, Cornwall MW, Medoff L, Vicenzino B, Forsberg K, Hiltz D. Arch height change during sit-to-stand: an alternative for the navicular drop test. *J Foot Ankle Res.* 2008;1(1):3. doi:10.1186/1757-1146-2-17.
- Cornwall MW, McPoil TG. Relationship between static foot posture and foot mobility. *J Foot Ankle Res.* 2011;4:4. doi:10.1186/1757-1146-4-4.
- Spörndly-Nees S, Däsberg B, Nielsen RO, Boesen MI, Langberg H. The navicular position test: a reliable measure of the navicular bone position during rest and loading. *Int J Sports Phys Ther.* 2011;6(3):199-205.
- McPoil TG, Vicenzino B, Cornwall MW, Collins N, Warren M. Reliability and normative values for the foot mobility magnitude: a composite measure of vertical and medial-lateral mobility of the midfoot. *J Foot Ankle Res.* 2009;2:6. doi:10.1186/1757-1146-2-6.
- Stein M, Shlamkovitch N, Finestone A, Milgrom C. Marcher's digitalgia paresthetica among recruits. *Foot Ankle.* 1989;9(6):312-313.
- Seddon HJ. A classification of nerve injuries. *Br Med J.* 1942;2(4260):237-239.
- Sleszynski SL, Glonek T. Outpatient osteopathic SOAP note form: preliminary results in osteopathic outcomes-based research. *J Am Osteopath Assoc.* 2005;105(4):181-205.

© 2014 American Osteopathic Association