

## Elevated Factor VIII: An Unfamiliar Risk Factor for Cerebral Venous Thrombosis

Nicole E. Albert, DO  
Andrew Y. Hamarich, OMS IV  
Ami Joshi, DO, MBA

**An elevated factor VIII level has been shown to be an independent risk factor for venous thrombosis. However, physicians screen for this factor far less frequently than they screen for other coagulopathies. The causes of increased factor VIII levels are likely a combination of genetic and acquired variables. The authors describe a case of a healthy 48-year-old woman found to have a cerebral venous thrombosis, with her only identifiable risk factor being an elevated factor VIII level.**

*J Am Osteopath Assoc.* 2012;112(3):140-141

An elevated factor VIII level has been shown to be an independent risk factor for venous thrombosis.<sup>1</sup> The molecular basis for the increased level of this factor is not completely understood, but it is likely a combination of inherited and acquired variables.<sup>2</sup> Elevations in factor VIII may account for as many as 16% of venous thrombotic events, yet physicians screen for this factor far less frequently than they do for other coagulopathies.<sup>3</sup> We present the case of a healthy woman found to have a cerebral venous thrombosis, with her only identifiable risk factor being a substantially elevated factor VIII level.

### Report of Case

A 48-year-old African American woman with a past medical history of anxiety presented to the emergency room with an acute change in mental status. The patient's husband reported that she had been in her usual state of health with the exception of a headache the day before presentation. On the morning

of admission, the patient went grocery shopping and on her return appeared confused and disoriented. The patient's husband also reported that her gait was unsteady and that she had an episode of urinary incontinence.

The patient was not taking any medications or supplements and consumed 6 beers daily. Family history included breast cancer in her mother and prostate cancer in her father. On physical examination, the patient was afebrile and hemodynamically stable with a Glasgow Coma Scale score of 11. During neurologic examination, the patient was combative, spoke inappropriately, and was indifferent to her surroundings. However, she had equally round and reactive pupils and full range of motion in all 4 extremities.

Laboratory findings were normal. Results of a urinary drug screen and noncontrast computed tomography of the brain performed on the day of admission were unremarkable. A lumbar puncture was performed; cerebral spinal fluid testing was negative for white blood cells and revealed a protein level of 75 mg/dL and glucose level of 86 mg/dL. The patient was given empiric intravenous thiamine hydrochloride and acyclovir sodium for Wernicke encephalopathy and herpes encephalitis. On hospital day 2, magnetic resonance imaging of the brain revealed new hydrocephalus, and an electroencephalogram showed changes consistent with diffuse encephalopathy of nonspecific origin. Results of contrast-enhanced computed tomography of the chest, abdomen, and pelvis were unremarkable. On hospital day 4, cerebrospinal fluid testing was negative for bacterial, fungal, and acid fast cultures and cryptococcal antigens, and the patient was given methylprednisolone (125 mg intravenously). On day 5, cerebrospinal fluid testing for herpes simplex virus returned negative results and acyclovir was discontinued. On day 6, the patient was showing little improvement, so magnetic resonance angiography/venography was performed. This imaging revealed thromboses of the paired deep internal cerebral veins, the Galen vein, and the straight sinus (*Figure*).

After the diagnosis of a cerebral vein thrombosis, warfarin therapy (7.5 mg daily) was initiated. Before diagnosis, a comprehensive panel was drawn for coagulopathies and vasculitides. These findings were negative for anticardiolipin antibody, lupus anticoagulant, factor V Leiden, factor II gene mutation,  $\beta_2$  glycoprotein 1 antibody, antinuclear antibody, cryoglobulinemia, antineutrophil cytoplasmic antibody-associated vasculitis, and human immunodeficiency virus. The patient's protein C and

From the Department of Internal Medicine at Lankenau Medical Center in Wynnewood, Pennsylvania (Drs Albert and Joshi), and the Philadelphia College of Osteopathic Medicine (Student Doctor Hamarich).

This case was a finalist at the American College of Osteopathic Internists poster competition, which was held on October 13, 2011, in San Antonio, Texas.

**Financial Disclosures:** None reported.

Address correspondence to Nicole E. Albert, DO, Department of Internal Medicine, Lankenau Medical Center, 100 E Lancaster Ave, Wynnewood, PA 19096-3415.

E-mail: albertn@mlhs.org

Submitted October 20, 2011; revision received December 17, 2011; accepted January 22, 2012.

protein S activity, protein electrophoresis, homocysteine levels, and thyroid stimulating hormone levels were normal. The only remarkable laboratory value was an elevated factor VIII assay at a level of 399% (reference range, 75% to 160%).

The patient remained in the hospital for 34 days. Her mental status improved substantially, and, at the time of discharge, she was oriented with an appropriate affect and able to answer questions properly. She was instructed to remain on warfarin (7.5 mg daily) indefinitely. The patient was followed up 2 weeks after discharge, at which time her husband reported that her mental status had returned to baseline (ie, mental status prior to the encephalopathic event).

### Comment

Elevations in factor VIII levels are thought to be an independent risk factor for venous thrombosis. Levels above 150% have been shown to be associated with a fivefold increased risk of venous thrombosis.<sup>1</sup> Additionally, patients with a factor VIII level above the 90th percentile have been shown to have a 37% risk of recurrence at 2 years, suggesting that factor VIII hyperactivity may also be an independent risk factor for recurrent venous thrombosis.<sup>4</sup> To our knowledge, there have been only a few cases<sup>5-7</sup> of cerebral vein thrombosis in the setting of elevated factor VIII levels. However, several studies have suggested that this derangement may account for a large number of these events. Cakmak et al<sup>4</sup> found that an elevated factor VIII level was the most common coagulopathy, occurring in 6 of 12 patients with cerebral vein thrombosis.

The exact basis for increases in factor VIII is not completely understood, but it is likely a combination of genetic and acquired variables.<sup>2</sup> Genetic factors such as increased von Willebrand factor levels and non-O blood groups have been associated with elevated factor VIII level.<sup>1,3</sup> An increase in factor VIII has been particularly noted to be more common in

the African American population. Patel et al<sup>8</sup> found levels above the 90th percentile in 34 of 100 black patients with a history of venous thrombosis, compared with 10% of black control patients. Additionally, the odds ratio for the risk of venous thrombosis for black patients with elevated factor VIII levels in this study was reported to exceed those reported for white patients.<sup>8</sup> Acquired factors, such as increased body mass index, hyperglycemia, hypertriglyceridemia, pregnancy, surgery, chronic inflammation, malignancy, liver disease, hyperthyroidism, intravascular hemolysis, and renal disease have been linked to increased levels as well.<sup>3,9</sup>

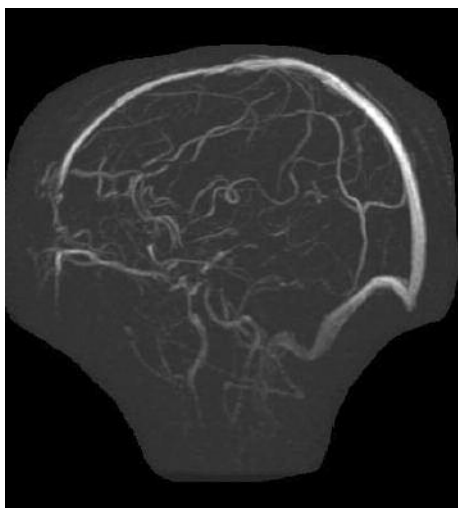
Several studies support the belief that an increase in factor VIII is the cause of thrombosis rather than the consequence. The risk for recurrent thrombosis has been shown to be as high as 37% in patients with high factor VIII levels, a risk that may warrant lifelong anticoagulation.<sup>10,11</sup> O'Donnell et al<sup>12</sup> showed that high factor VIII levels persist over time in patients with a cerebral vein thrombosis. Furthermore, Kyrle et al<sup>9</sup> and Kamphuisen et al<sup>3</sup> showed there is not a statistically significant relationship between plasma levels of factor VIII and C-reactive protein, suggesting that this factor is not an acute phase reactant.

### Conclusion

Patients who experience a thrombotic event should be evaluated for factor VIII hyperactivity in addition to other commonly screened genetic coagulopathies.

### References

1. Koster T, Blann AD, Briët E, Vandenbroucke JP, Rosendaal FR. Role of clotting factor VIII in effect of von Willebrand factor on occurrence of deep-vein thrombosis. *Lancet*. 1995;345(8943):152-155.
2. Hypercoagulable states. In: Hoffman R, Benz E, Shattil S, et al. *Hematology: Basic Principles and Practice*. Philadelphia, PA: Elsevier Churchill Livingstone; 2005.
3. Kamphuisen PW, Eikenboom JC, vos HL, et al. Increased levels of factor VIII and fibrinogen in patients with venous thrombosis are not caused by acute phase reactions. *Thromb Haemost*. 1999; 81(5):680-683.
4. Cakmak S, Derex L, Berruyer M, et al. Cerebral venous thrombosis: clinical outcome and systematic screening of prothrombotic factors. *Neurology*. 2003;60(7):1175-1178.
5. Kanazawa K, Takubo H, Nakamura Y, Ida M. Cerebral venous thrombosis with elevated factor VIII. *Intern Med*. 2010;49(14):1461-1462.
6. Maes J, Michotte A, Velkeniers B, Stadnik T, Jochmans K. Hyperthyroidism with increased factor VIII procoagulant protein as a predisposing factor for cerebral venous thrombosis. *J Neurol Neurosurg Psychiatry*. 2002;73(4):458.
7. Giraldo EA, Petrinjac-Nenadic R. The "cord sign" in cerebral venous thrombosis associated with high plasma levels of factor VIII. *Neurocrit Care*. 2011;15(1):186-189.
8. Patel RK, Ford E, Thumpston J, Arya R. Risk factors for venous thrombosis in the black population. *Thromb Haemost*. 2003;90(5):835-838.
9. Kyrle PA, Minar E, Hirschl M, et al. High plasma levels of factor VIII and the risk of recurrent venous thromboembolism. *N Engl J Med*. 2000;343(7):457-462.
10. Cristina L, Benilde C, Michela C, Mirella F, Giuliana G, Gualtiero P. High plasma levels of factor VIII and risk of recurrence of venous thromboembolism. *Br J Haematol*. 2004;124(4):504-510.
11. Kim MJ, Cho AH, No YJ, Kim HY, Kim JS. Recurrent cerebral venous thrombosis associated with elevated factor VIII. *J Clin Neurol*. 2006;2(4):286-289.
12. O'Donnell J, Mumford AD, Manning RA, Laffan M. Elevation of FVIII: C in venous thromboembolism is persistent and independent of the acute phase response. *Thromb Haemost*. 2000;83(1):10-13.



**Figure.** Magnetic resonance angiogram/venogram of the head of a 48-year-old woman. Imaging revealed thromboses of the paired deep internal cerebral veins, the Galen vein, and the straight sinus.